MS-1 Angiography Laboratory

James G. Smirniotopoulos, M.D.

Uniformed Services University of the Health Sciences
4301 Jones Bridge Road
Bethesda, MD 20814
Voice: 301-295-3145
FAX: 301-295-3893

Visit us on the WEB:
http://rad.usuhs.mil
http://rad.medpix.net

Radiology - http://rad.medpix.net

Angio Lab: Major Goals

- Normal Vascular Anatomy
  - Anastomoses and Circle of Willis
  - Vascular Territory on Axial Images
- Stenosis, Occlusion, and Infarction
- Vascular Variants and Malformations
  - Fetal origin of PCA
  - AVM
  - Cavernous Angioma
  - Venous Angioma
- Aneurysm and Subarachnoid Hemorrhage
- Hypertensive Disease

Radiology - http://rad.medpix.net

Carotid System

Carotid System

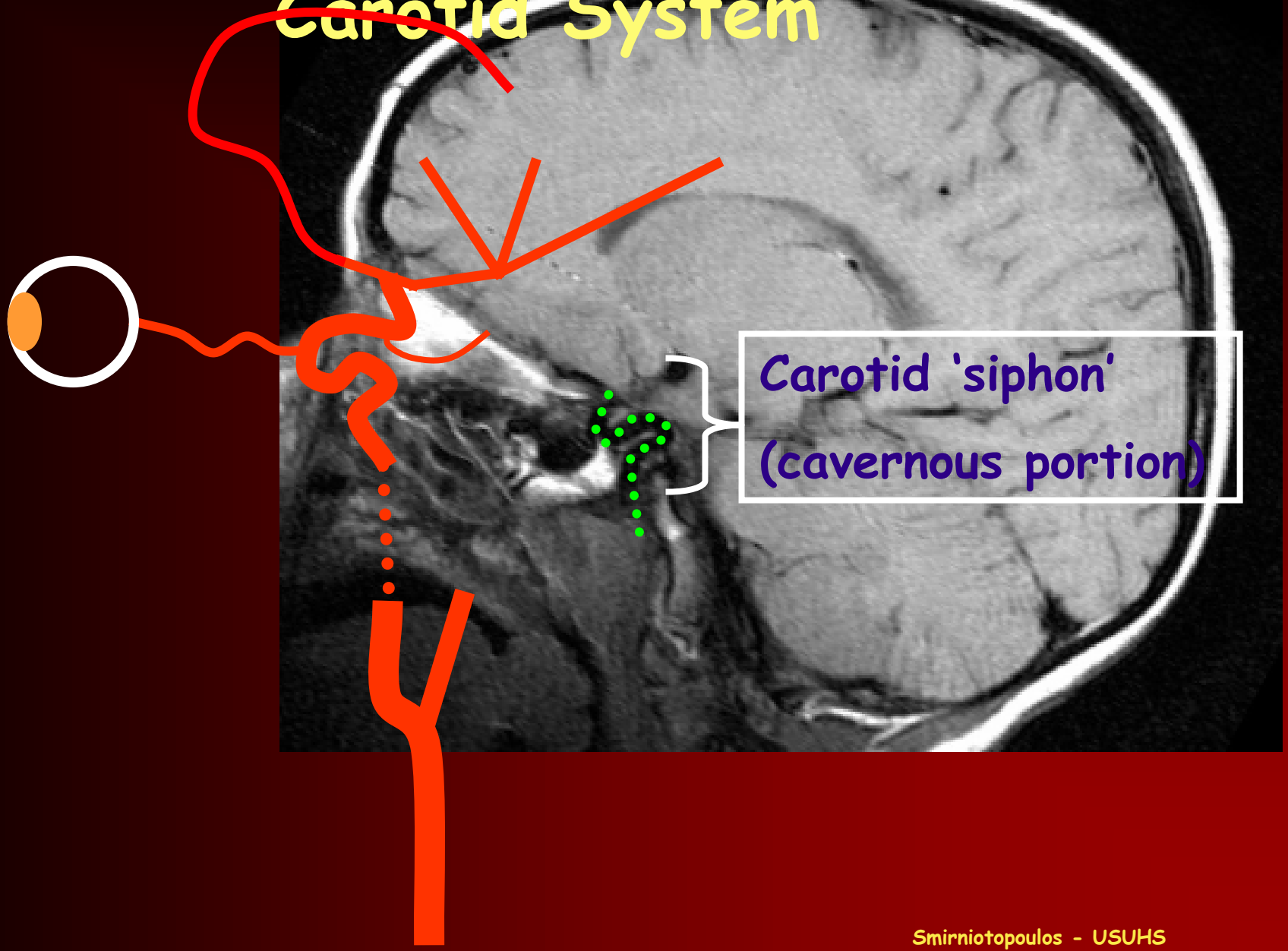

Radiology - http://rad.medpix.net

Carotid System

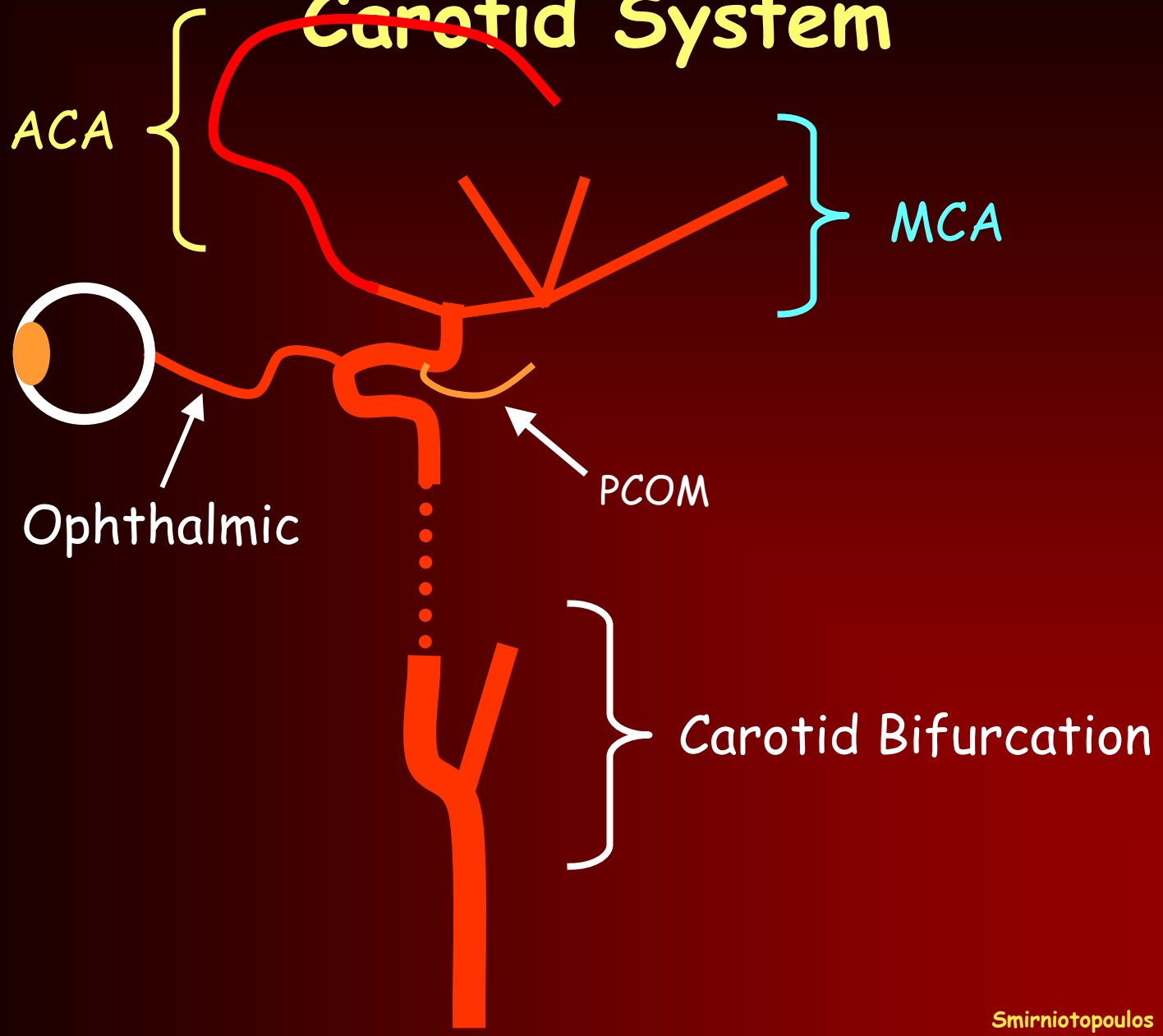

Radiology - http://rad.medpix.net

Sylvian Triangle - Insular Cortex

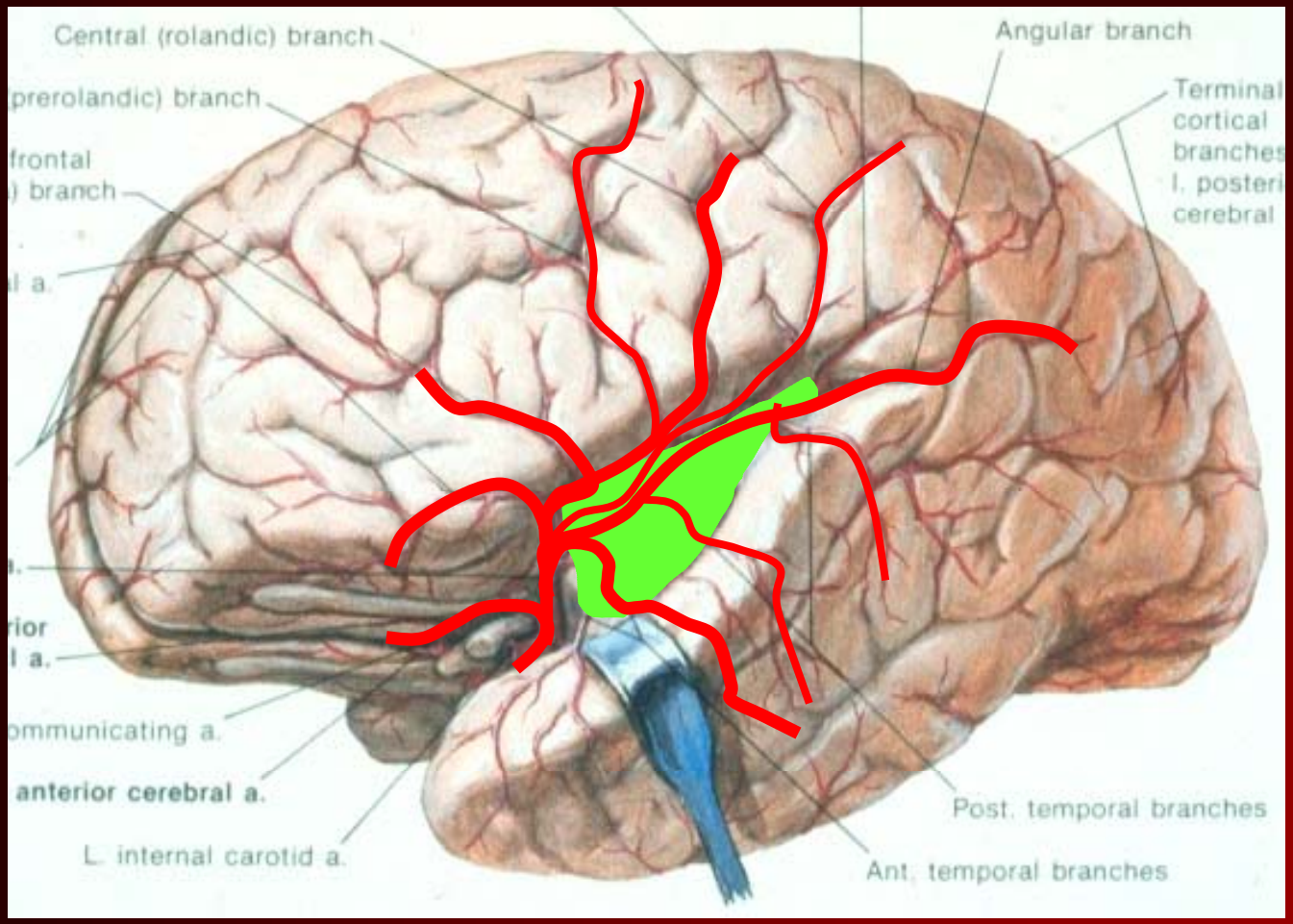

Insula (Insular Cortex)

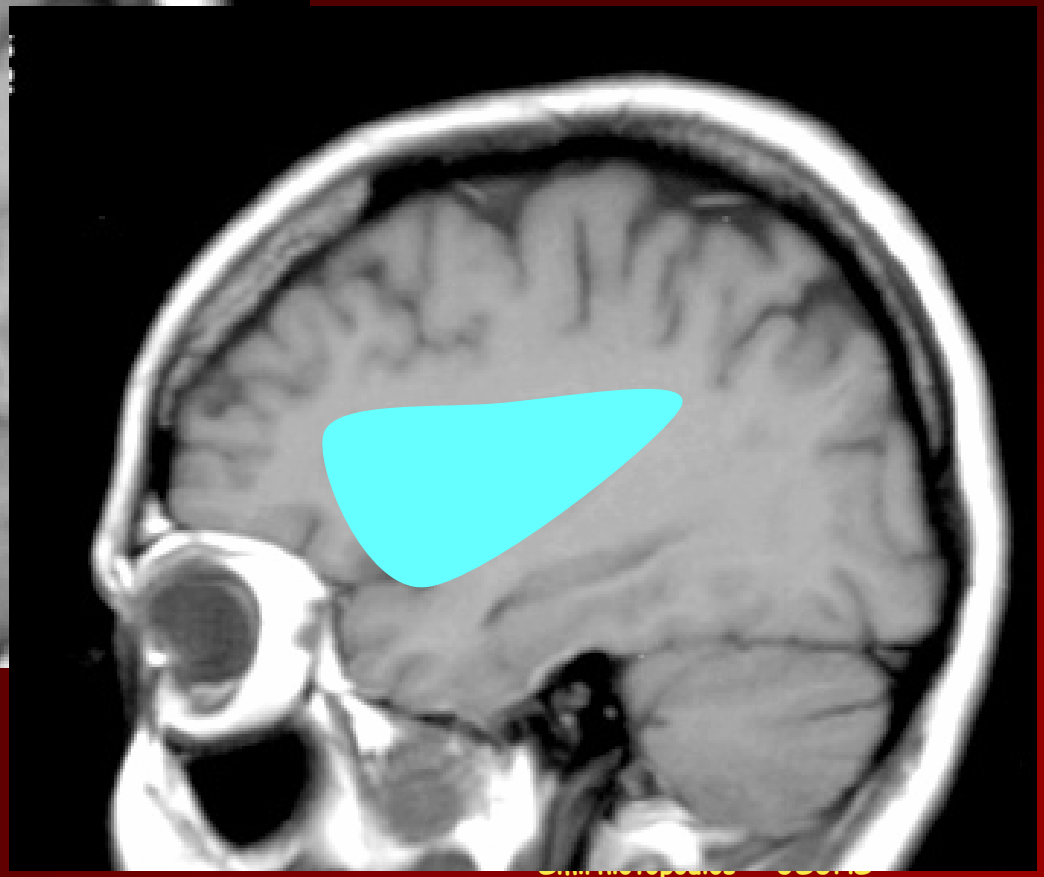

Radiology - http://rad.medpix.net

Sylvian Triangle

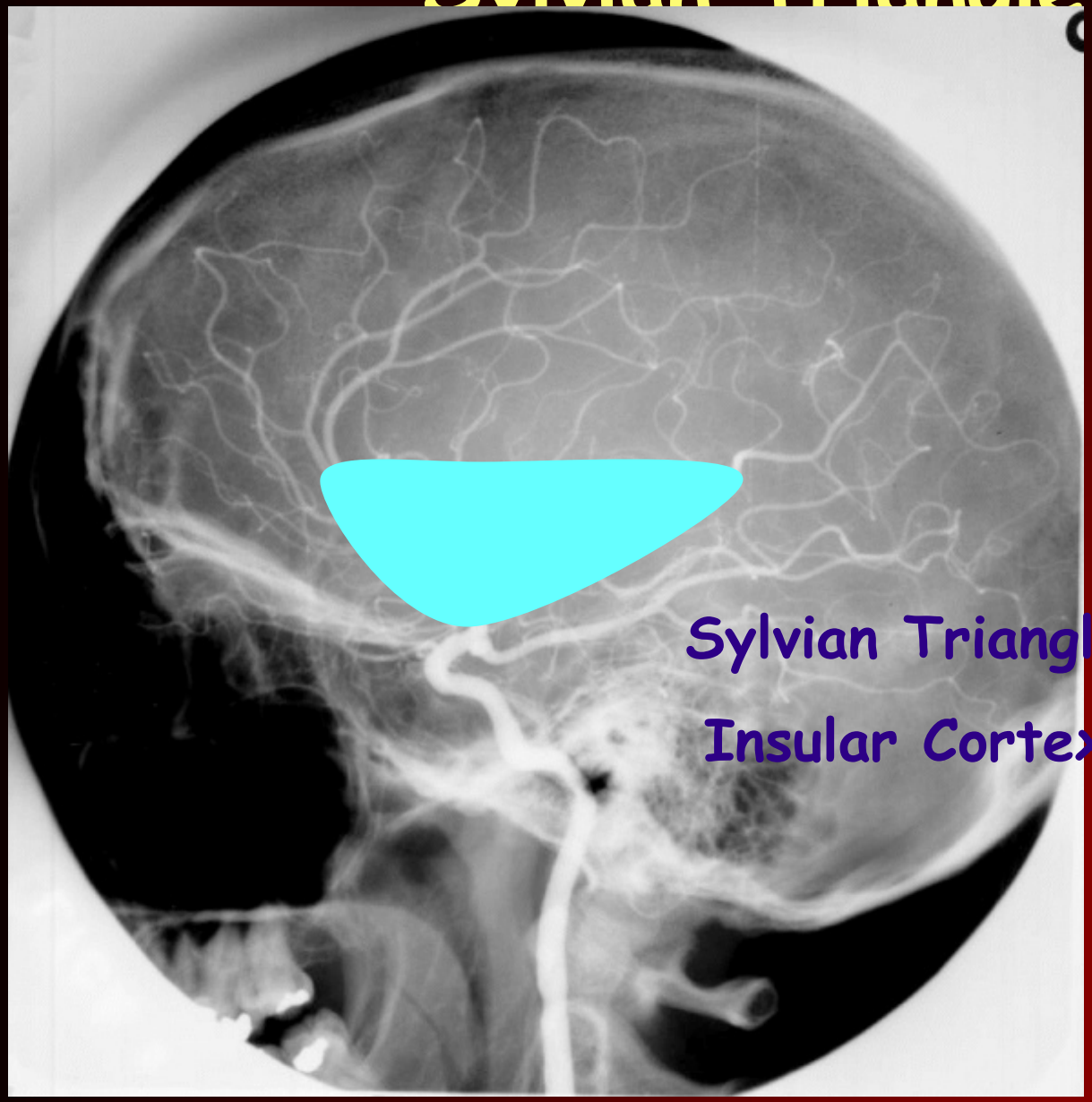

Radiology - http://rad.medpix.net

Lenticulostriate Vessels

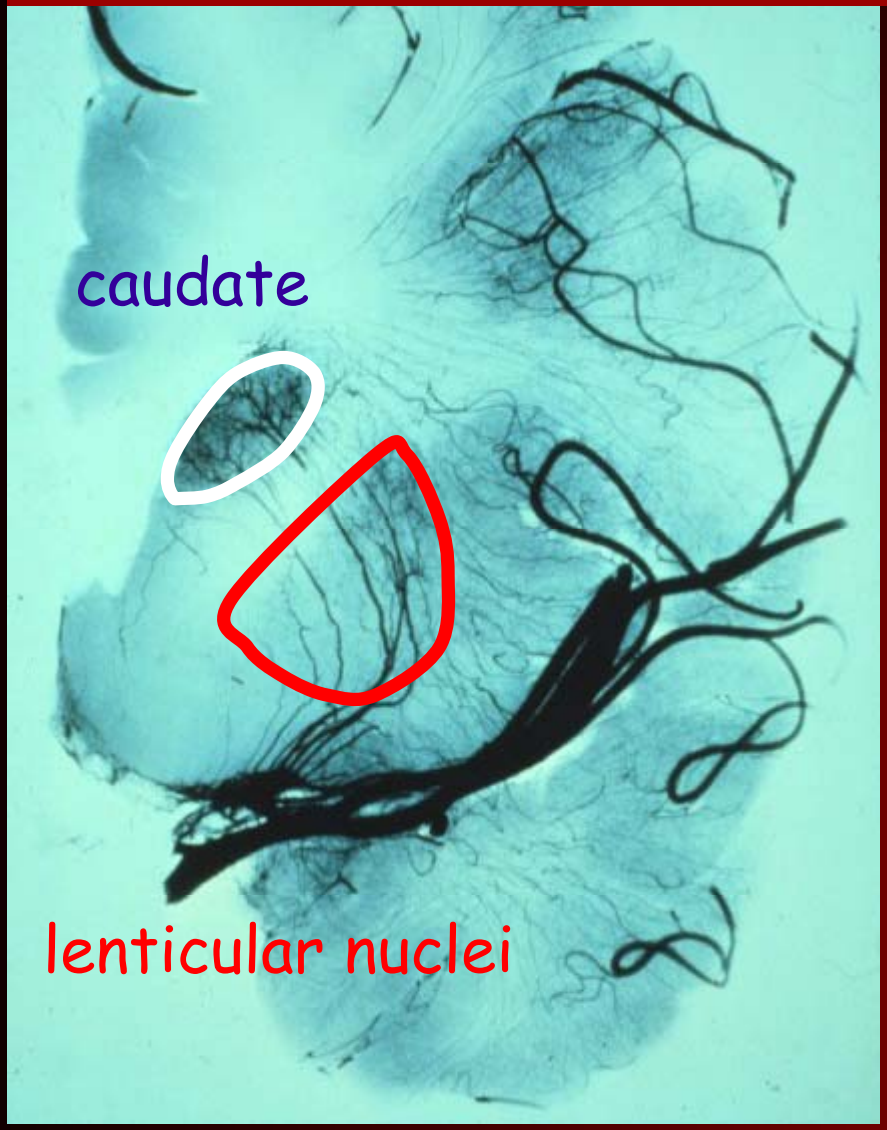

Basal Ganglia

- small caliber vessels
- non-anastomotic
- end-arteries
- arterioles

Hypertensive Disease

- hyalinized
- infarcts (lacunae)
- hemorrhage

Radiology - http://rad.medpix.net

Radiology - http://rad.medpix.net

Vertebrobasilar System

Frontal

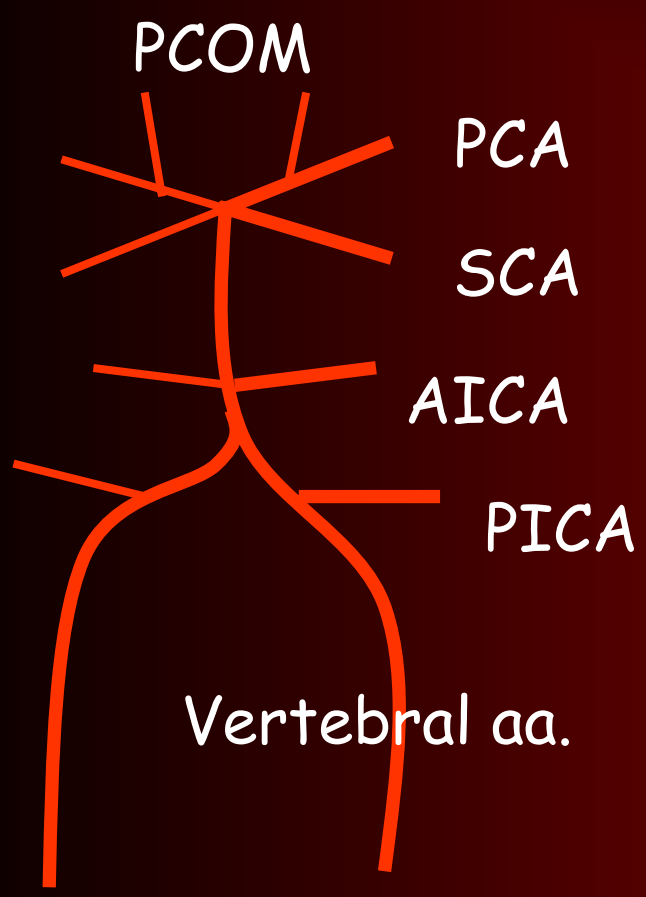

Lateral

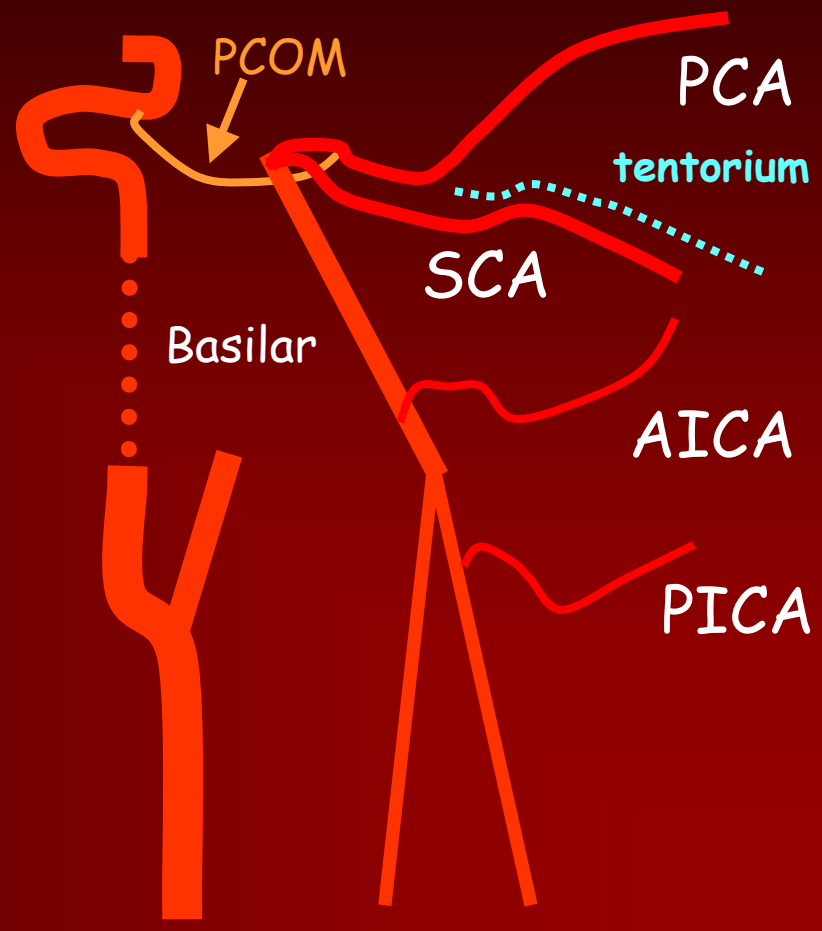

Smirniotopoulos - USUHS

Radiology - http://rad.medpix.net

Circle of Willis

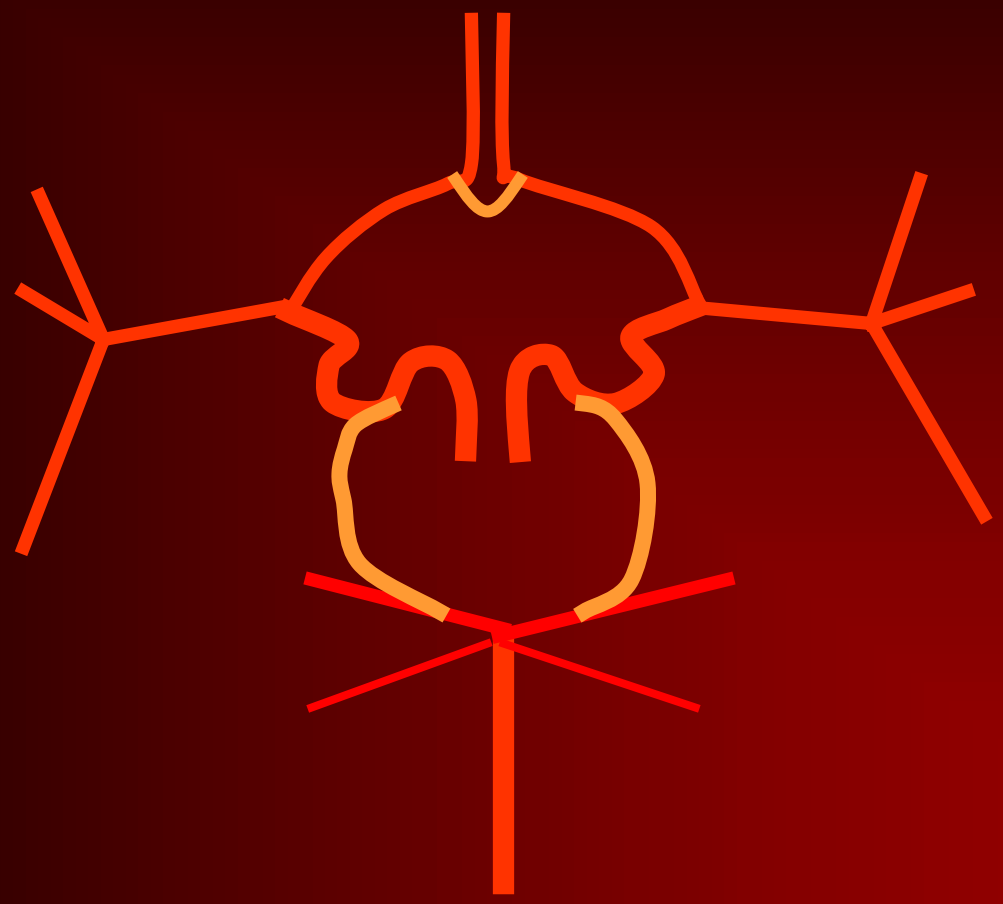

Radiology - http://rad.medpix.net

Circle of Willis

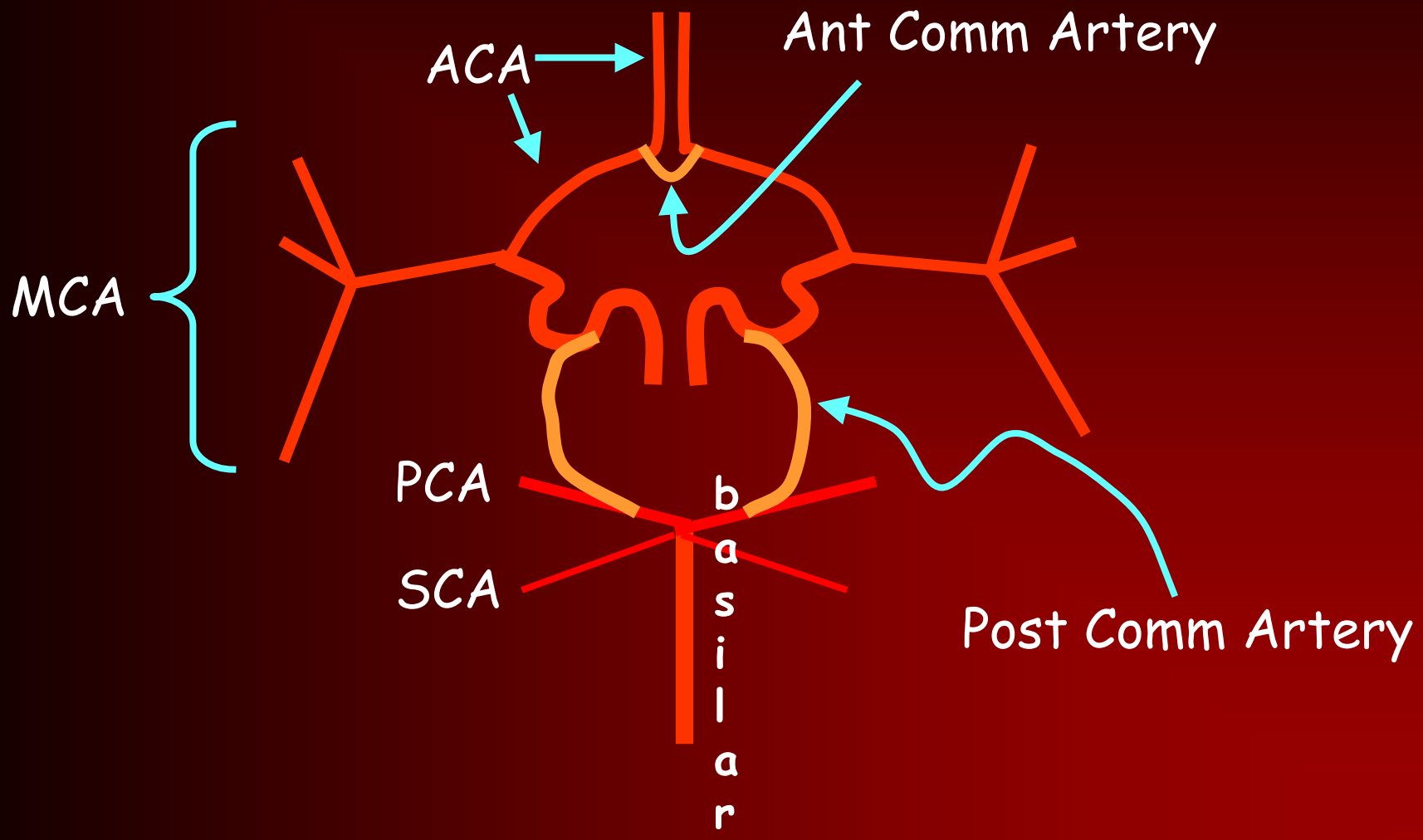

Carotid and Basilar Systems

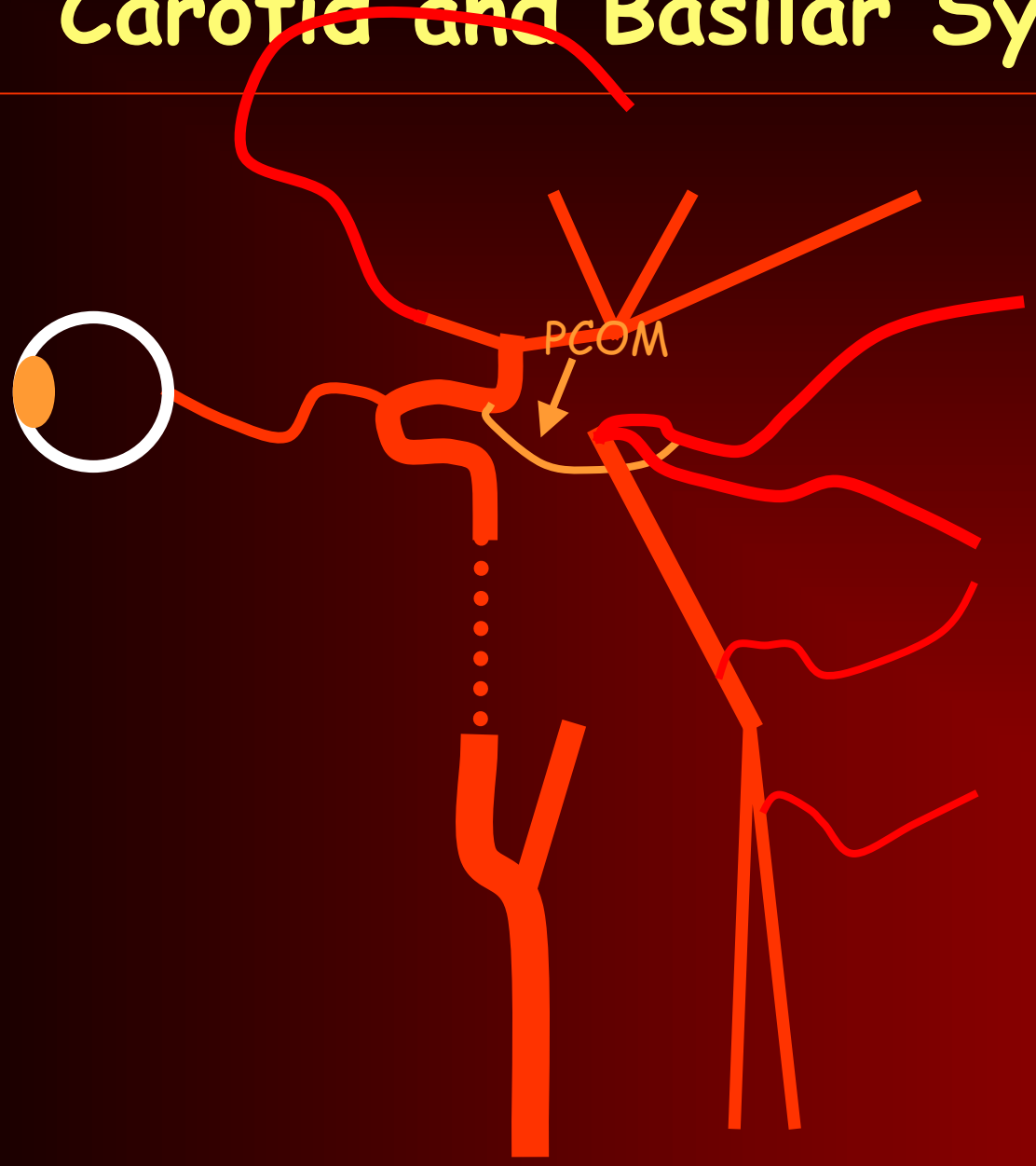

Radiology - http://rad.medpix.net

Carotid and Basilar Systems

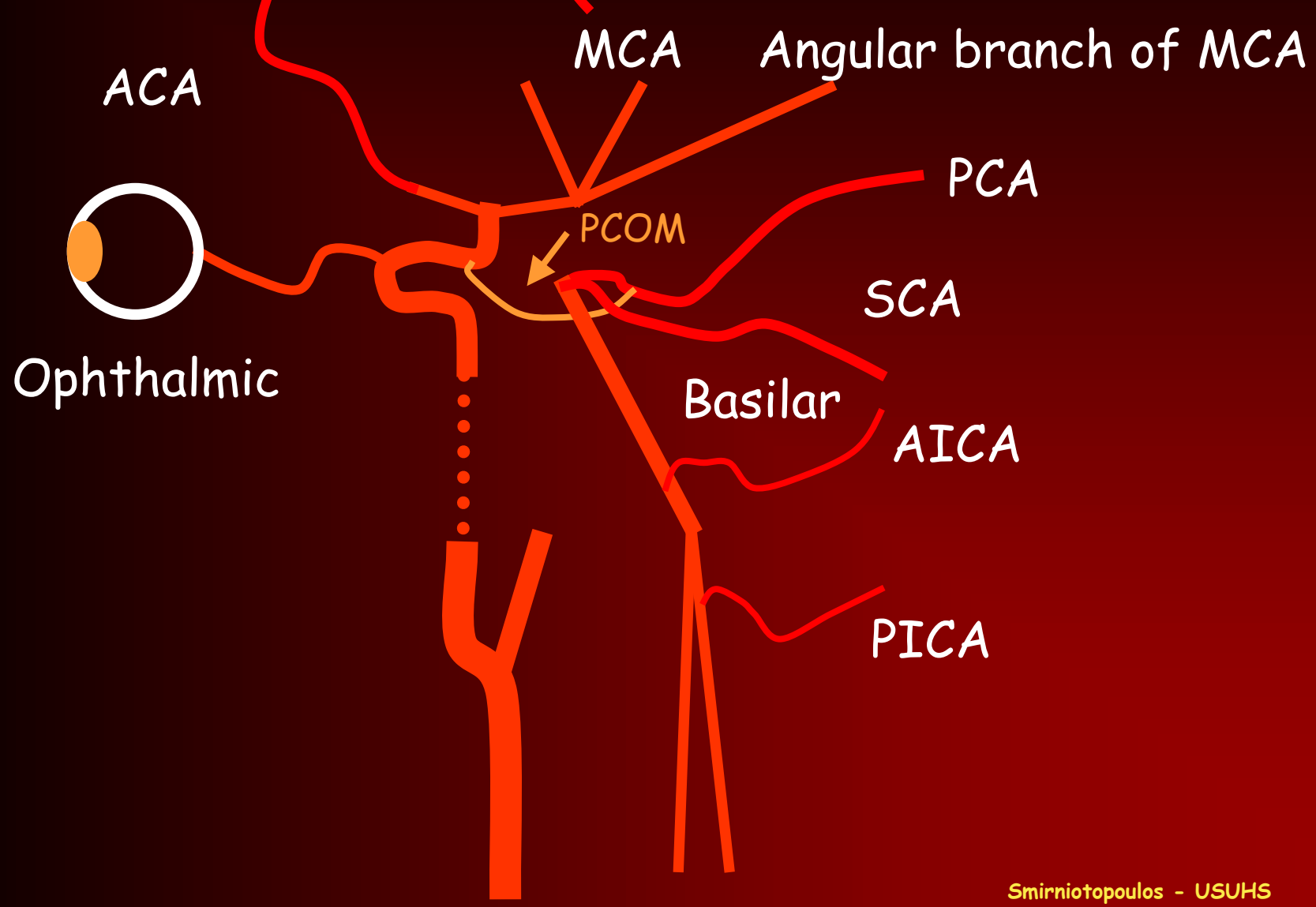

Radiology - http://rad.medpix.net

ICA Angiogram - Lateral

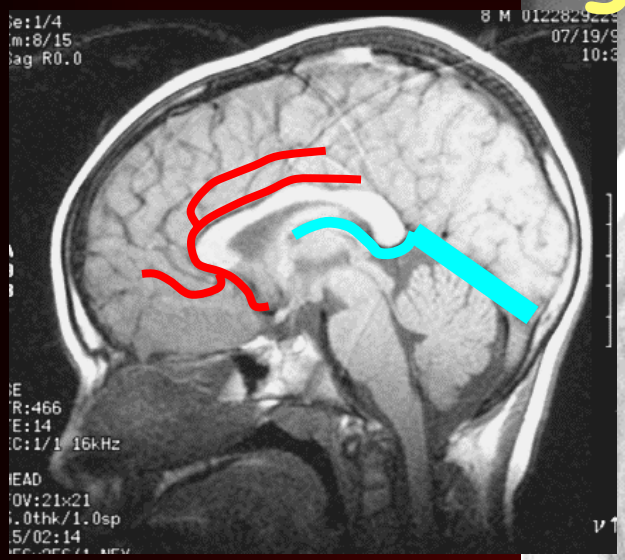

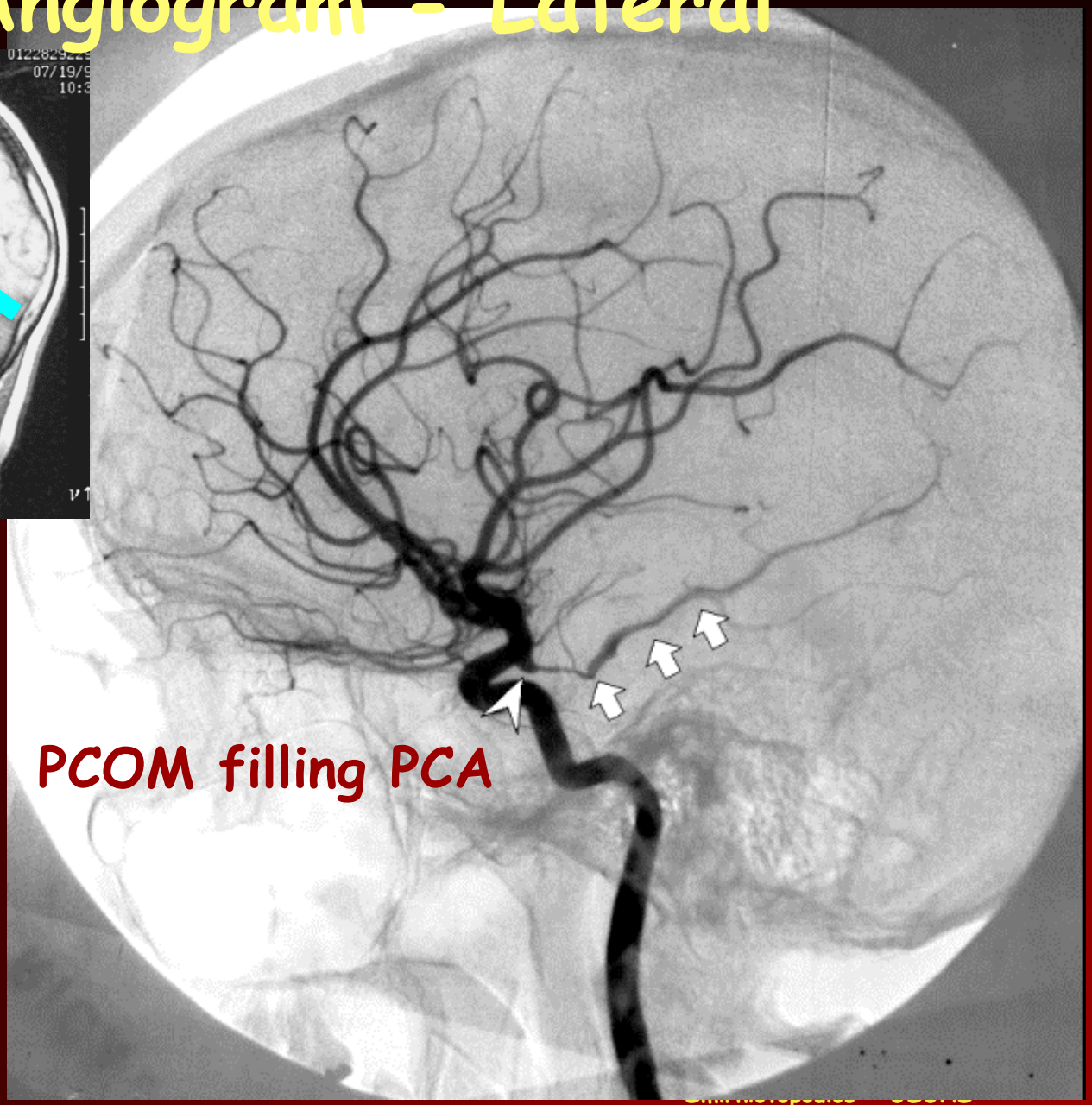

Radiology - http://rad.medpix.net

Sagittal T1W MRI

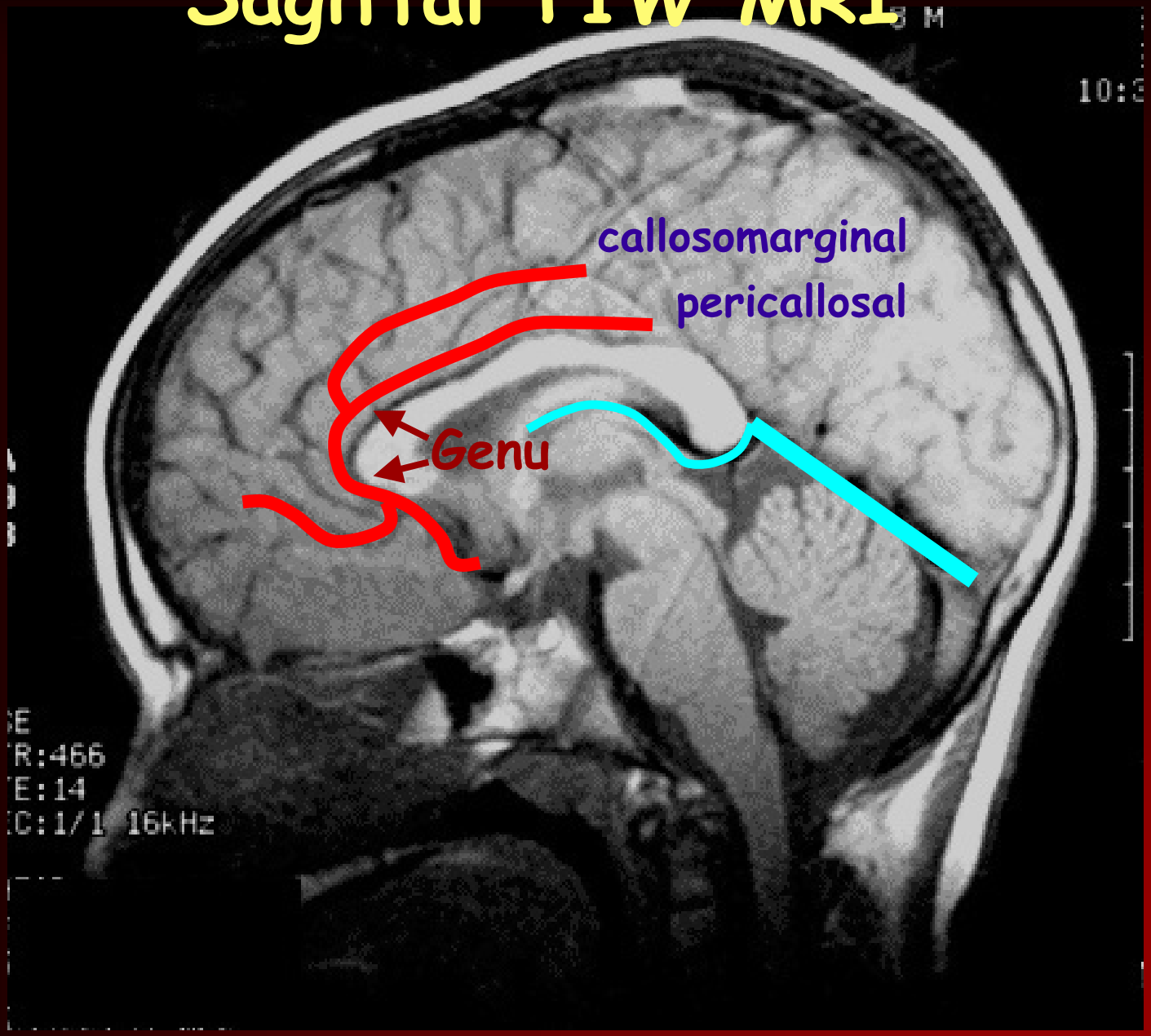

Radiology - http://rad.medpix.net

Fetal Origin of PCA

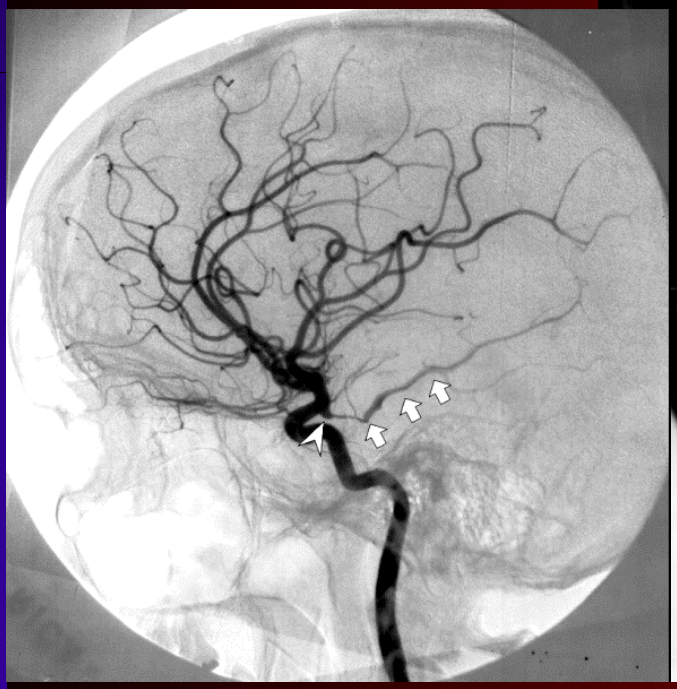

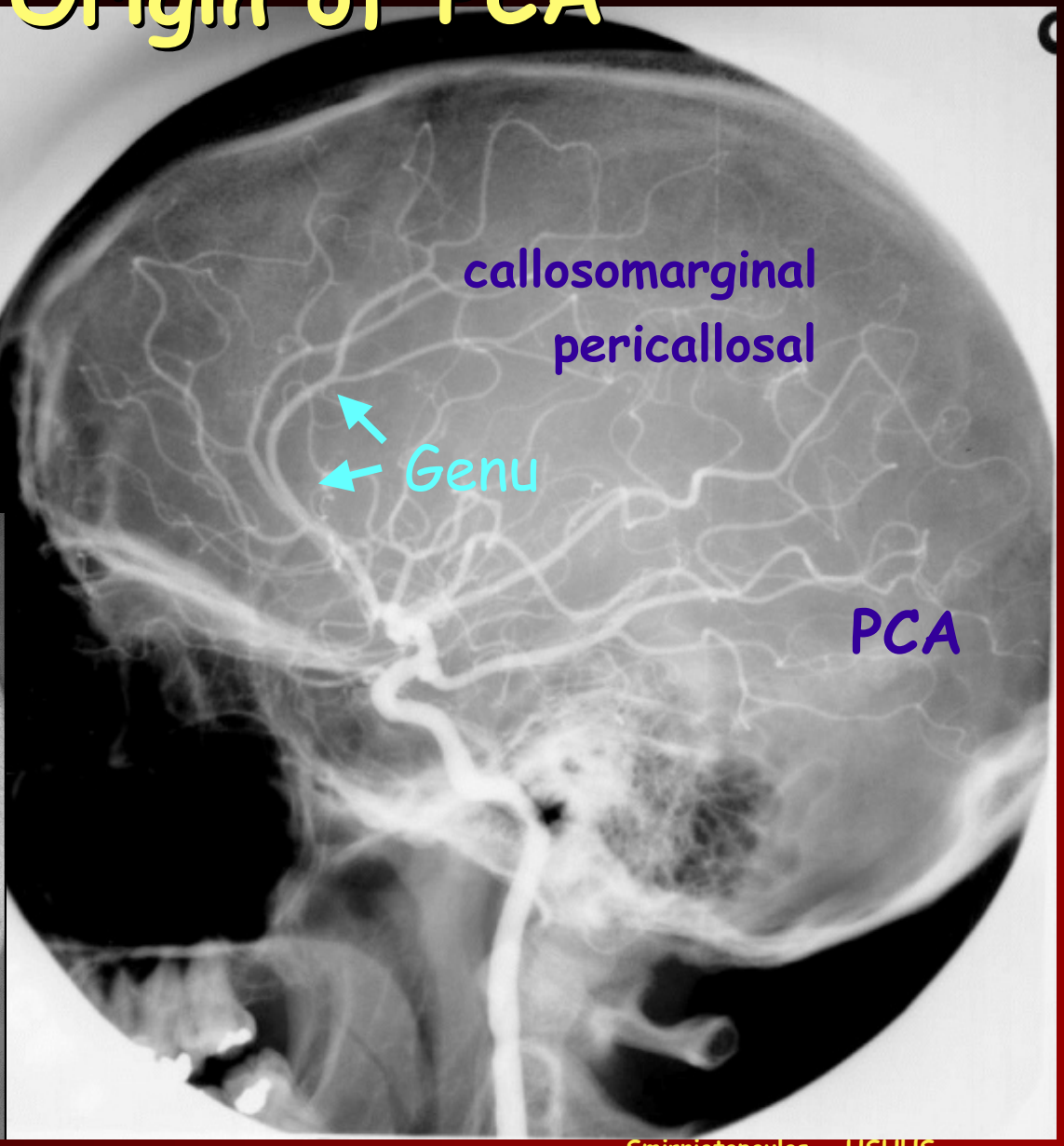

Radiology - http://rad.medpix.net

Radiology - http://rad.medpix.net

Angio Lab: Major Goals

- Normal Vascular Anatomy
  - Anastomoses and Circle of Willis
  - Vascular Territory on Axial Images
- Stenosis, Occlusion, and Infarction
- Vascular Variants and Malformations
  - Fetal origin of PCA
  - AVM
  - Cavernous Angioma
  - Venous Angioma
- Aneurysm and Subarachnoid Hemorrhage
- Hypertensive Disease

Vascular Territory:

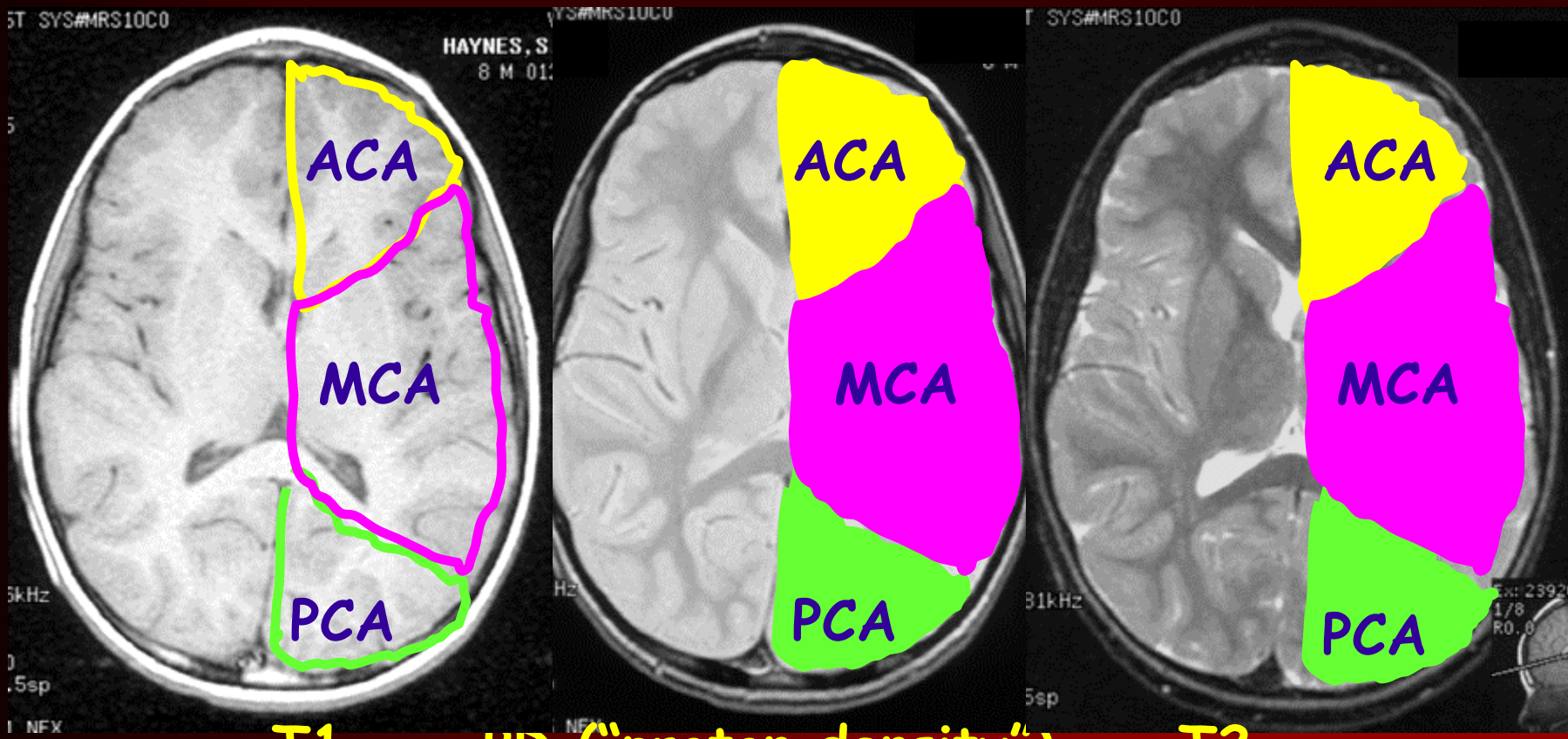

T1 PD ("proton density") T2

Radiology - http://rad.medpix.net

Radiology - http://rad.medpix.net

Hypotension and "Borderzone"

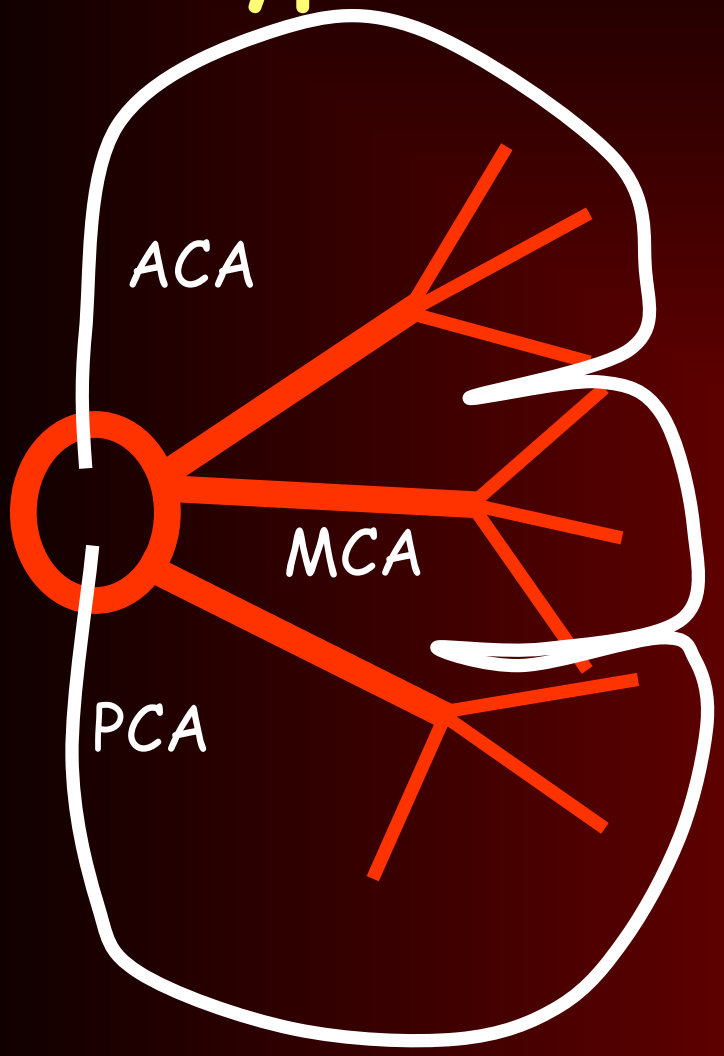

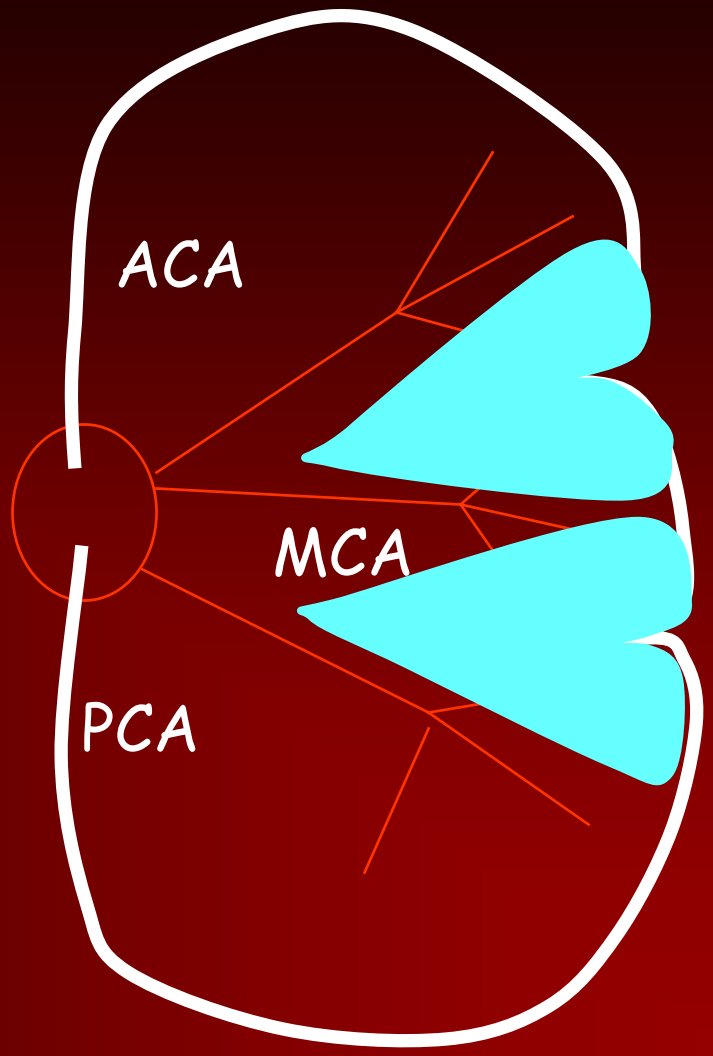

Hypotension and "Borderzone"

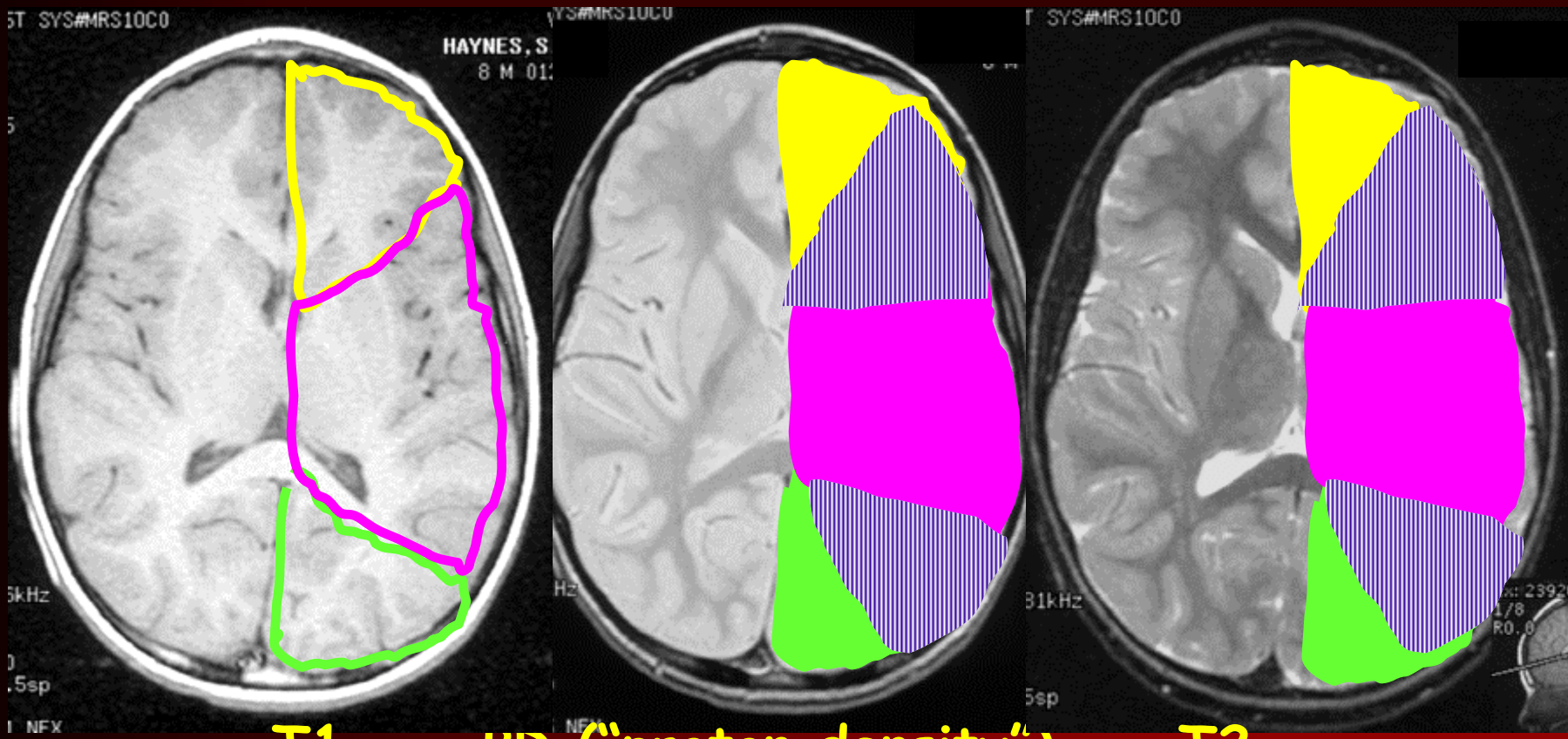

T1 PD ("proton density") T2

Border Zone Infarcts

Radiology - http://rad.medpix.net

Radiology - http://rad.medpix.net

Single Vessel Occlusion - MCA

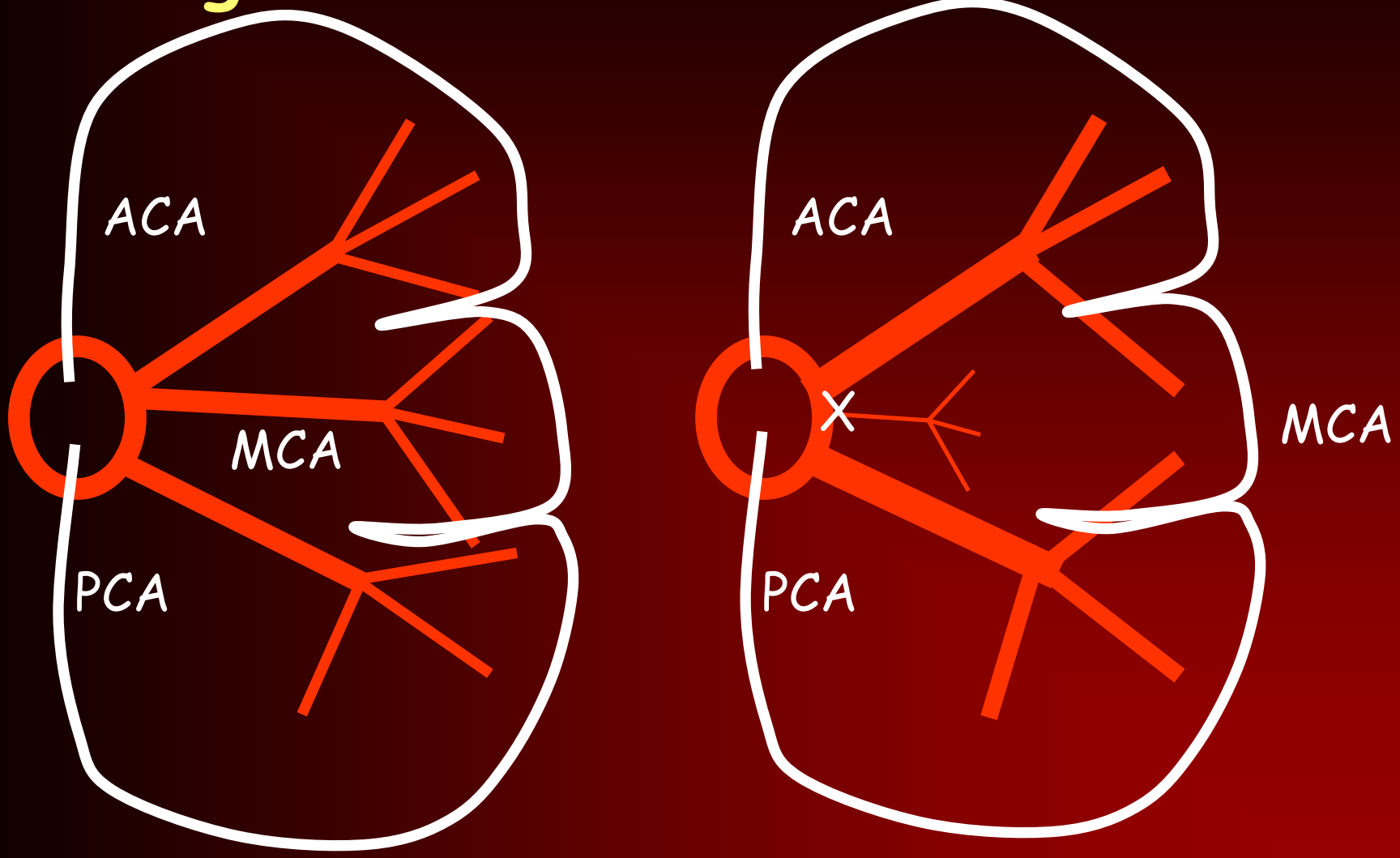

Flow is redistributed into patent vessels

Radiology - http://rad.medpix.net

Angio Lab: Major Goals

- Normal Vascular Anatomy
  - Anastomoses and Circle of Willis
  - Vascular Territory on Axial Images
- Stenosis, Occlusion, and Infarction
- Vascular Variants and Malformations
  - Fetal origin of PCA
  - AVM
  - Cavernous Angioma
  - Venous Angioma
- Aneurysm and Subarachnoid Hemorrhage
- Hypertensive Disease

Carotid Bifurcation



Early Turbulence => scarring => stenosis Late

Radiology - http://rad.medpix.net

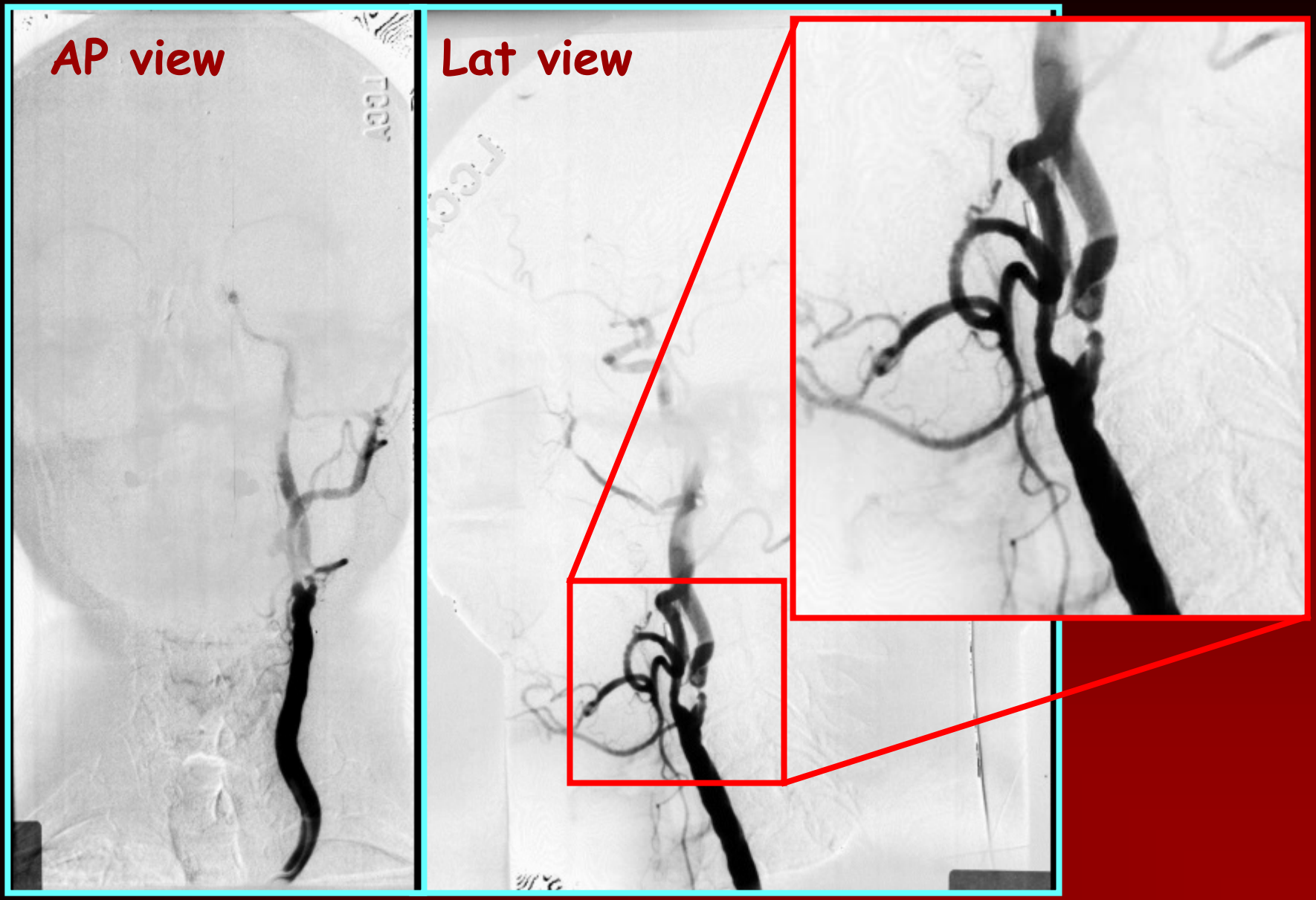

MRA - Magnetic Resonance Angiography

Radiology - http://rad.medpix.net

Bifurcation: Plaque and Thrombus

Radiology - http://rad.medpix.net

ICA Angiogram - Lateral

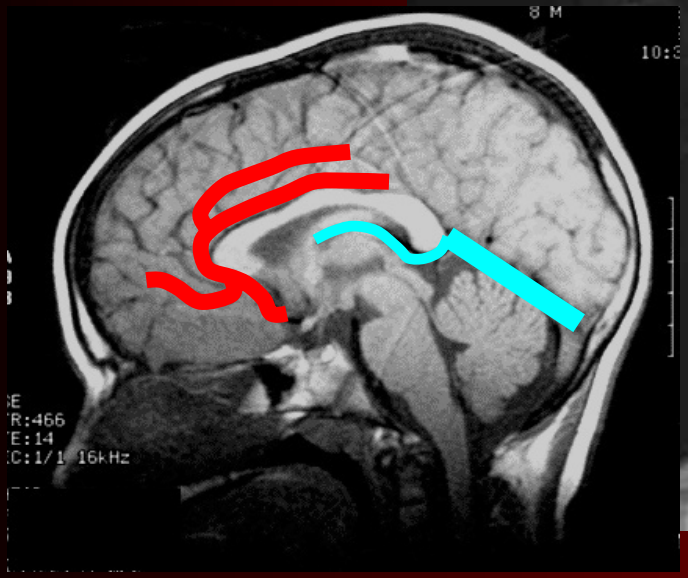

Smirniotopoulos - USUHS

Radiology - http://rad.medpix.net

ICA Angiogram - Lateral

Remember normal Sylvian triangle

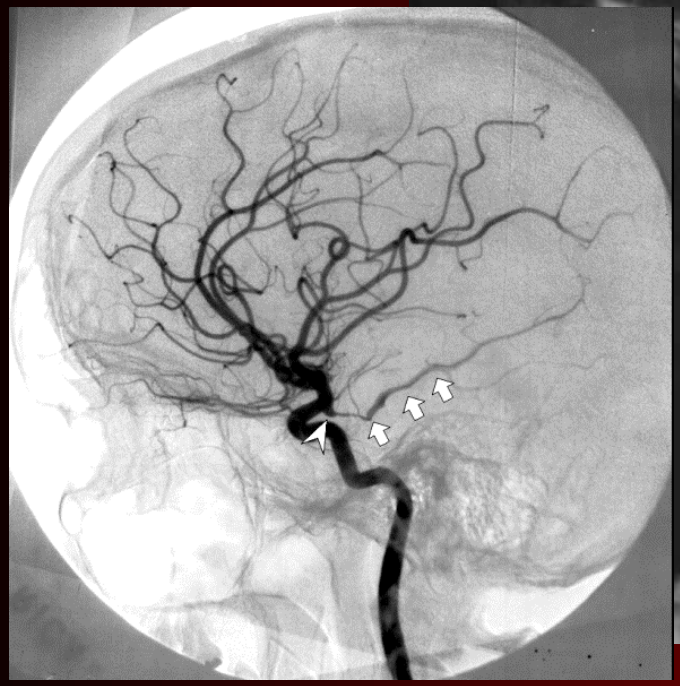

Missing vessels

Radiology - http://rad.medpix.net

ICA Angiogram - Lateral

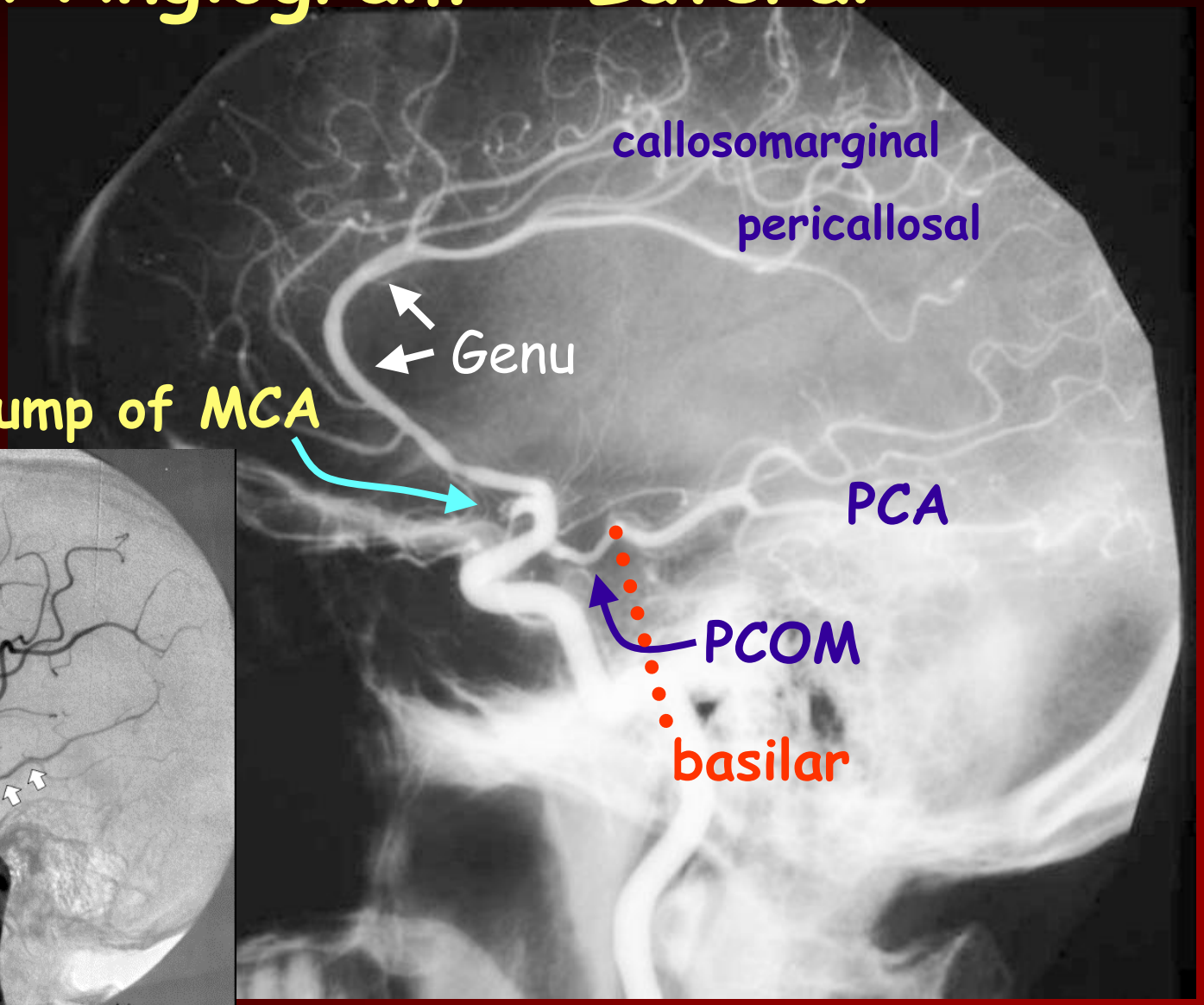

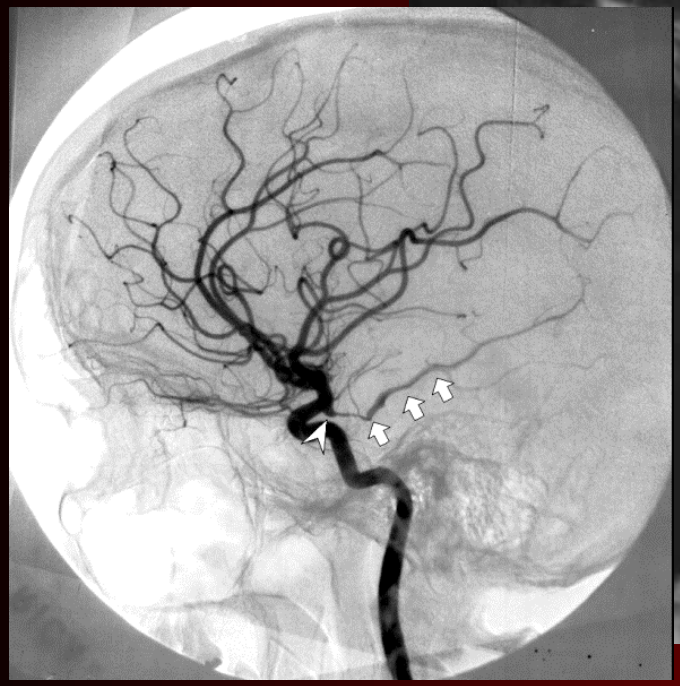

Radiology - http://rad.medpix.net

Carotid Thrombosis => MCA Clot

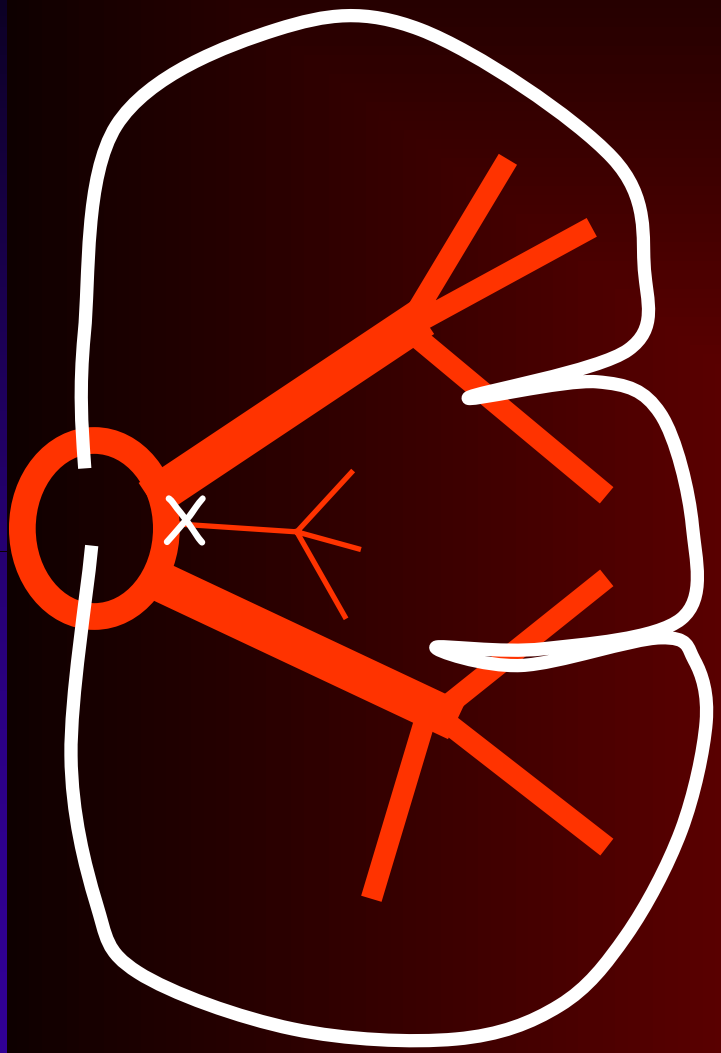

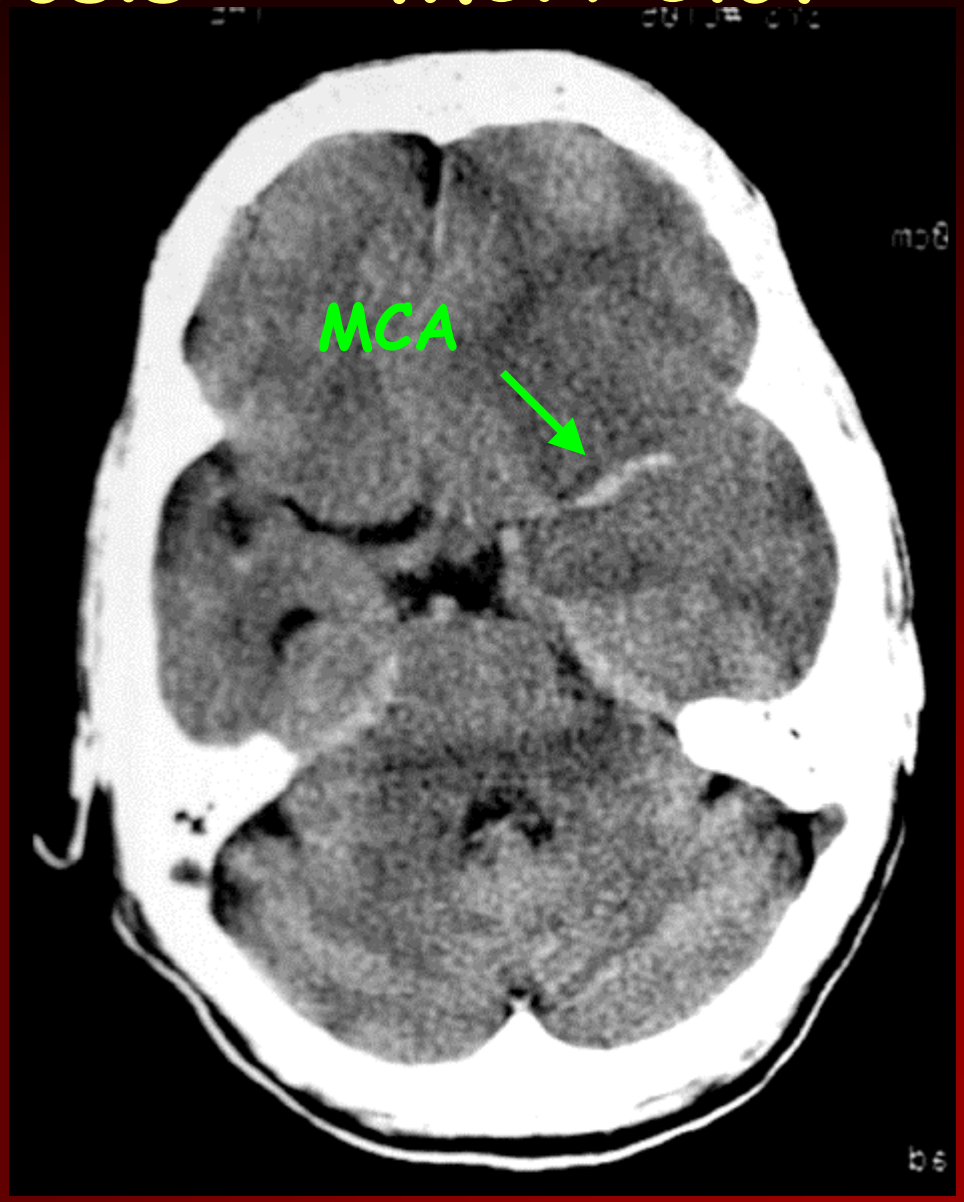

Smirniotopoulos - USUHS

Radiology - http://rad.medpix.net

MCA Vascular Territory

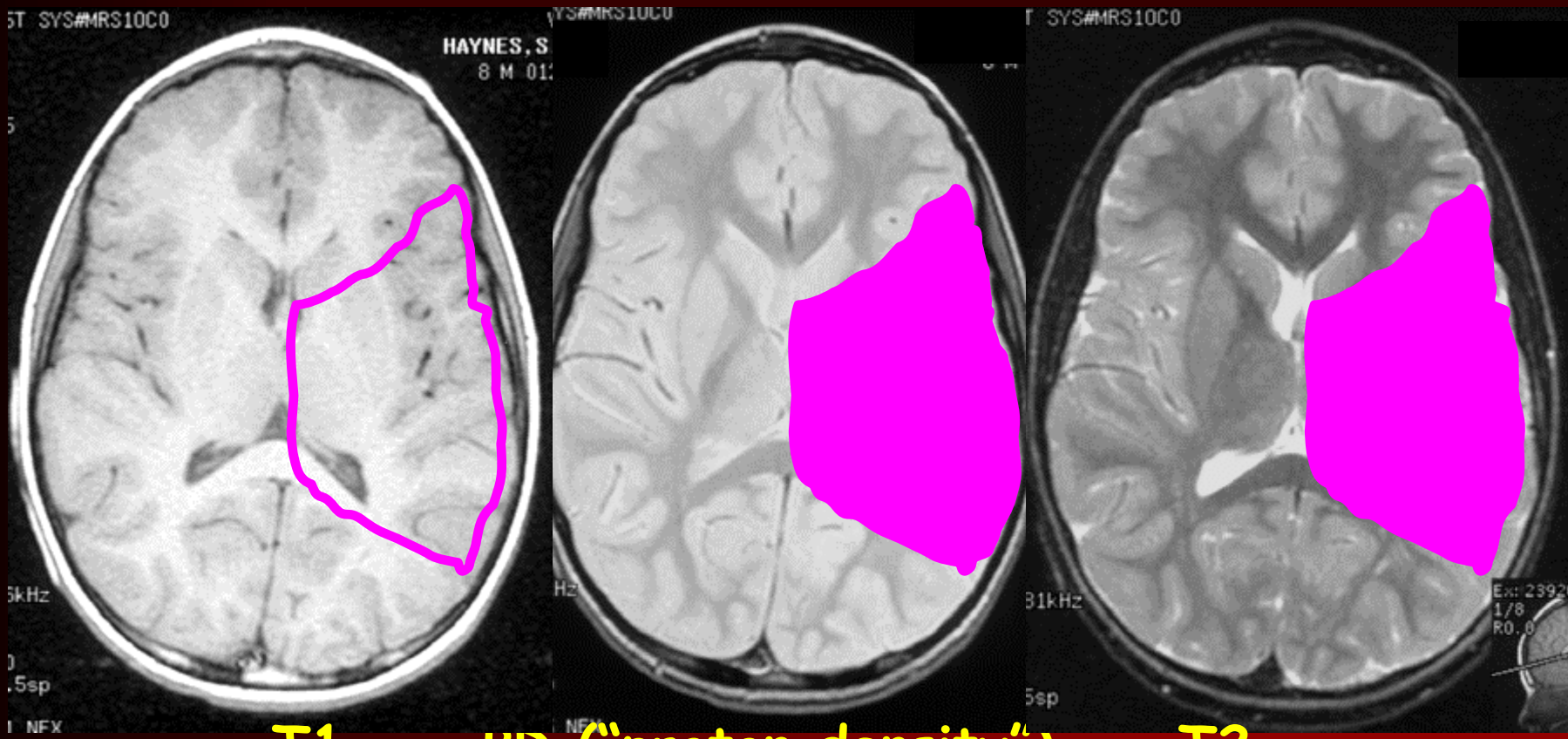

T1 PD ("proton density") T2

Radiology - http://rad.medpix.net

Whole MCA Infarction

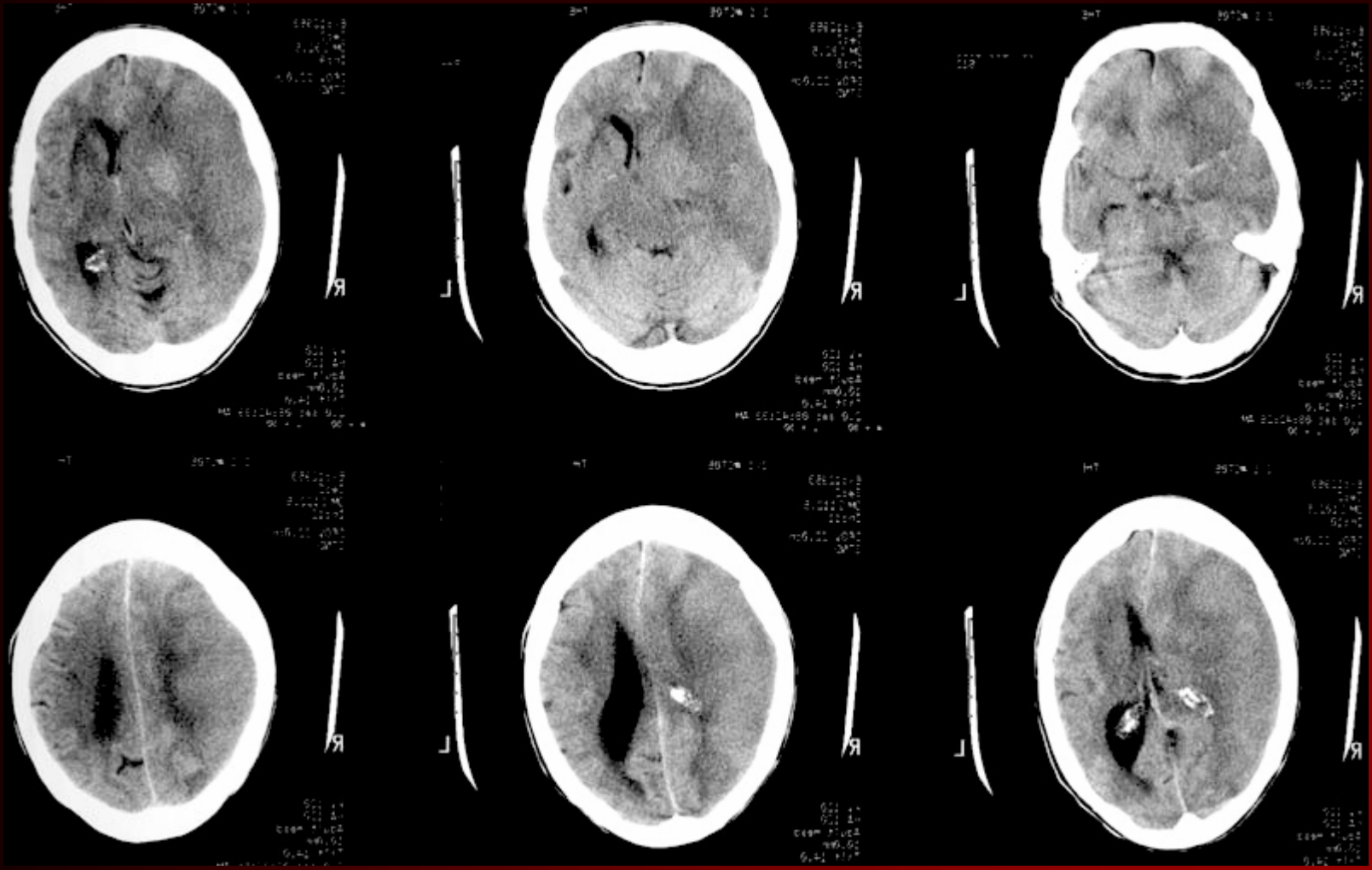

Radiology - http://rad.medpix.net

MCA Infarct: T1W and T2W MR

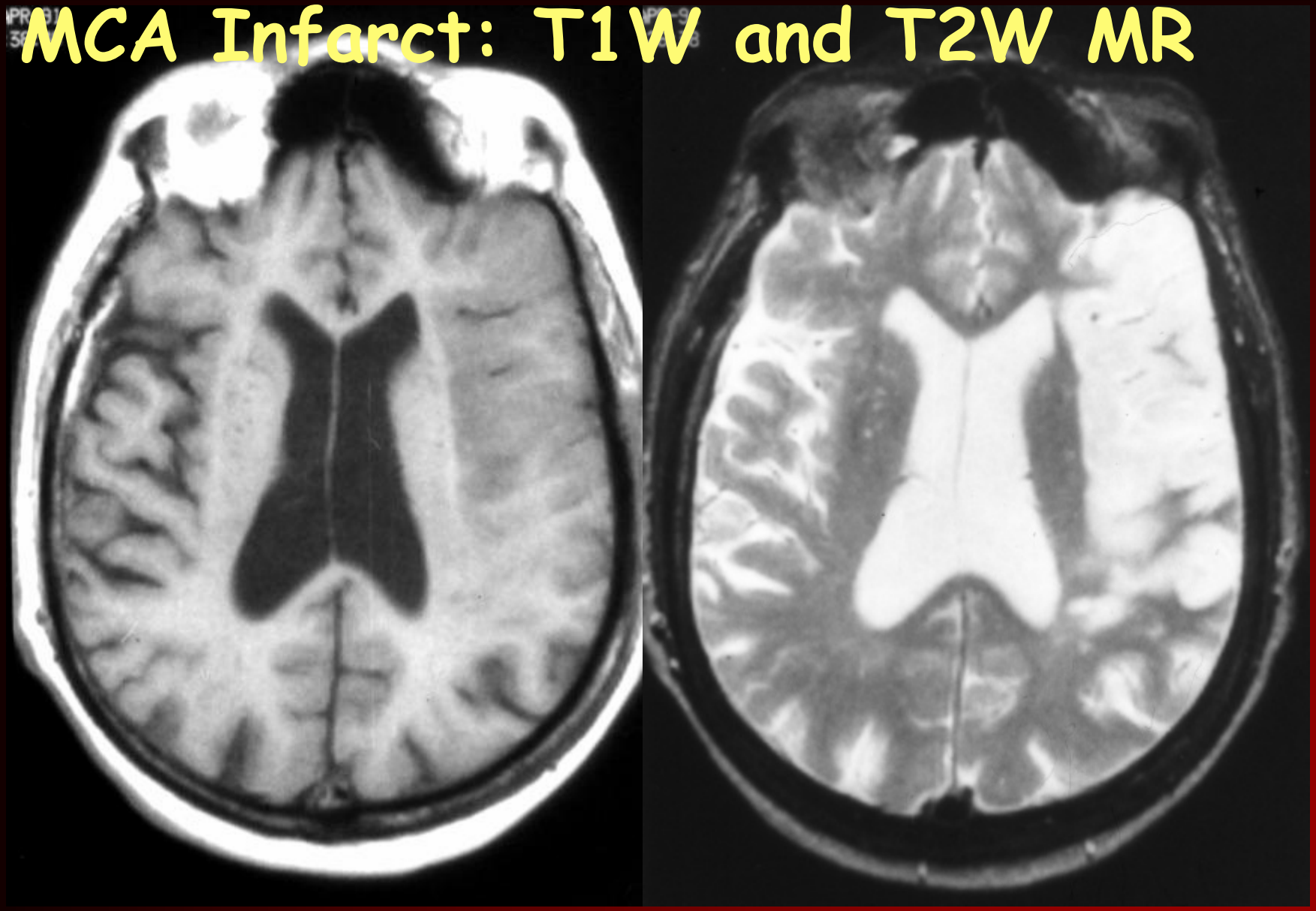

Radiology - http://rad.medpix.net

Partial MCA Infarct

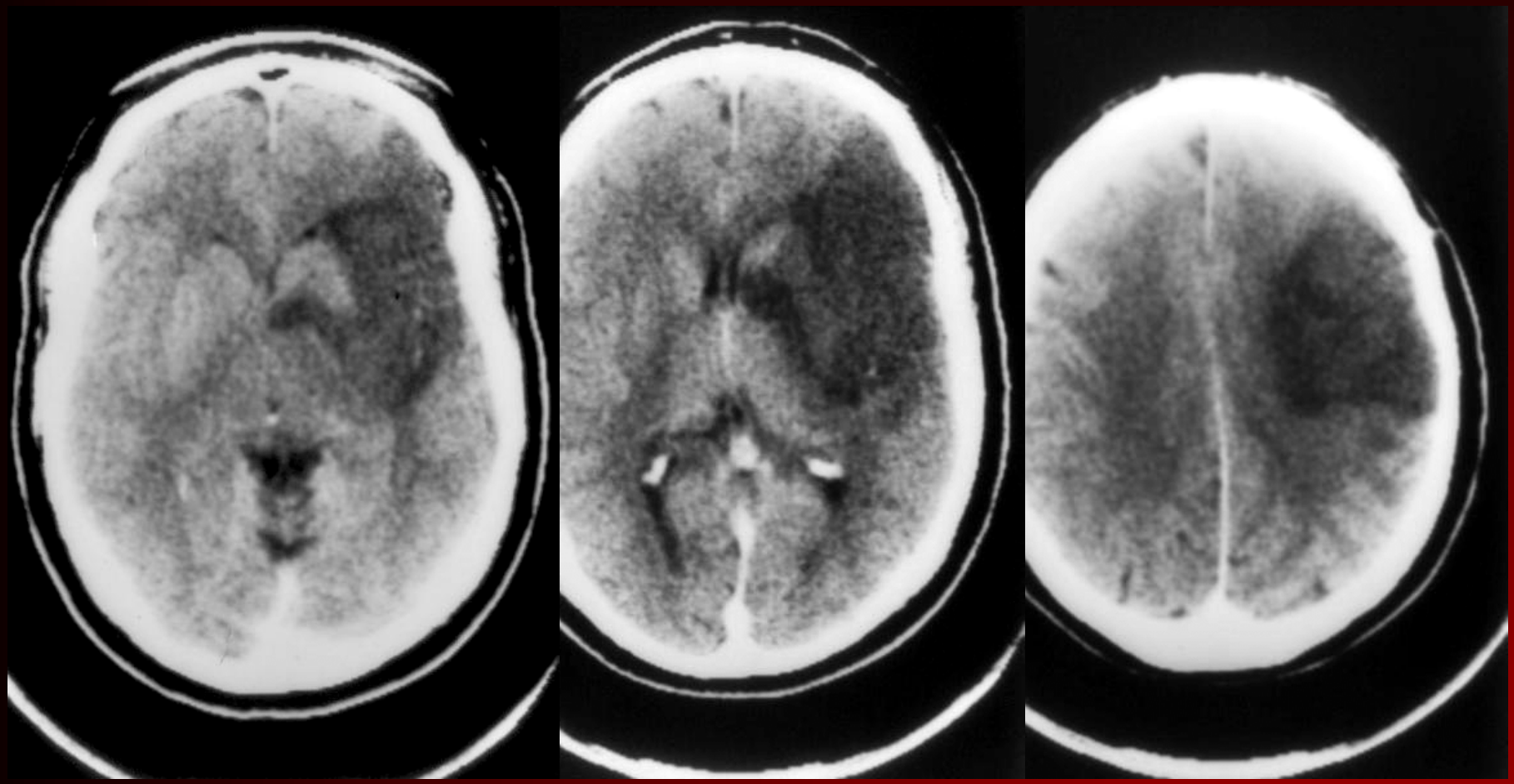

Radiology - http://rad.medpix.net

Radiology - http://rad.medpix.net

CEREBRAL INFARCTION

- Abrupt Onset
- Gray Matter Involved
- Little Mass Effect
  - nothing added
  - dead brain cells
- Vascular Territory & Wedge Shape

Small MCA Infarct

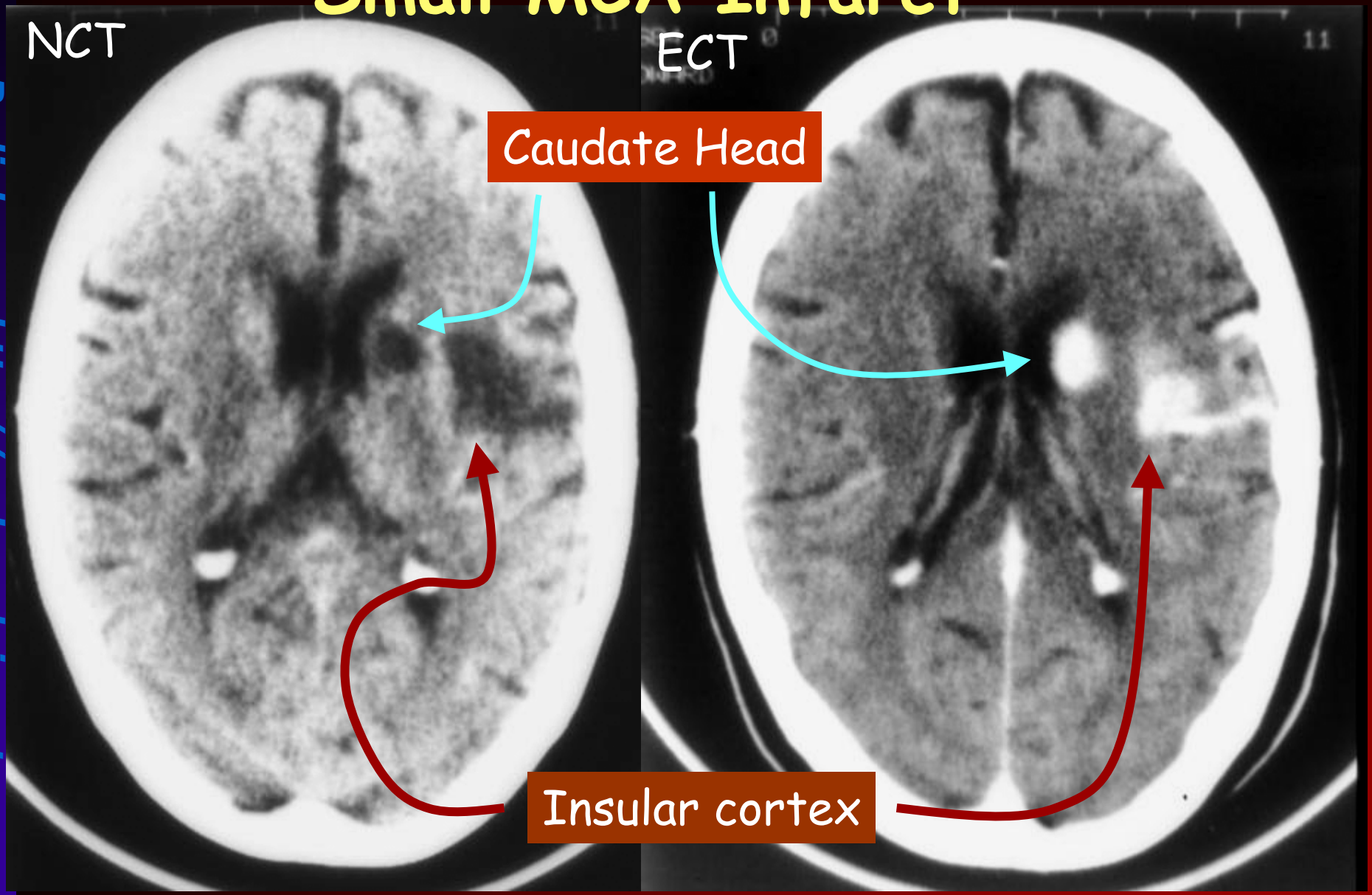

Radiology - http://rad.medpix.net

CVA: Progression Over 3 Days

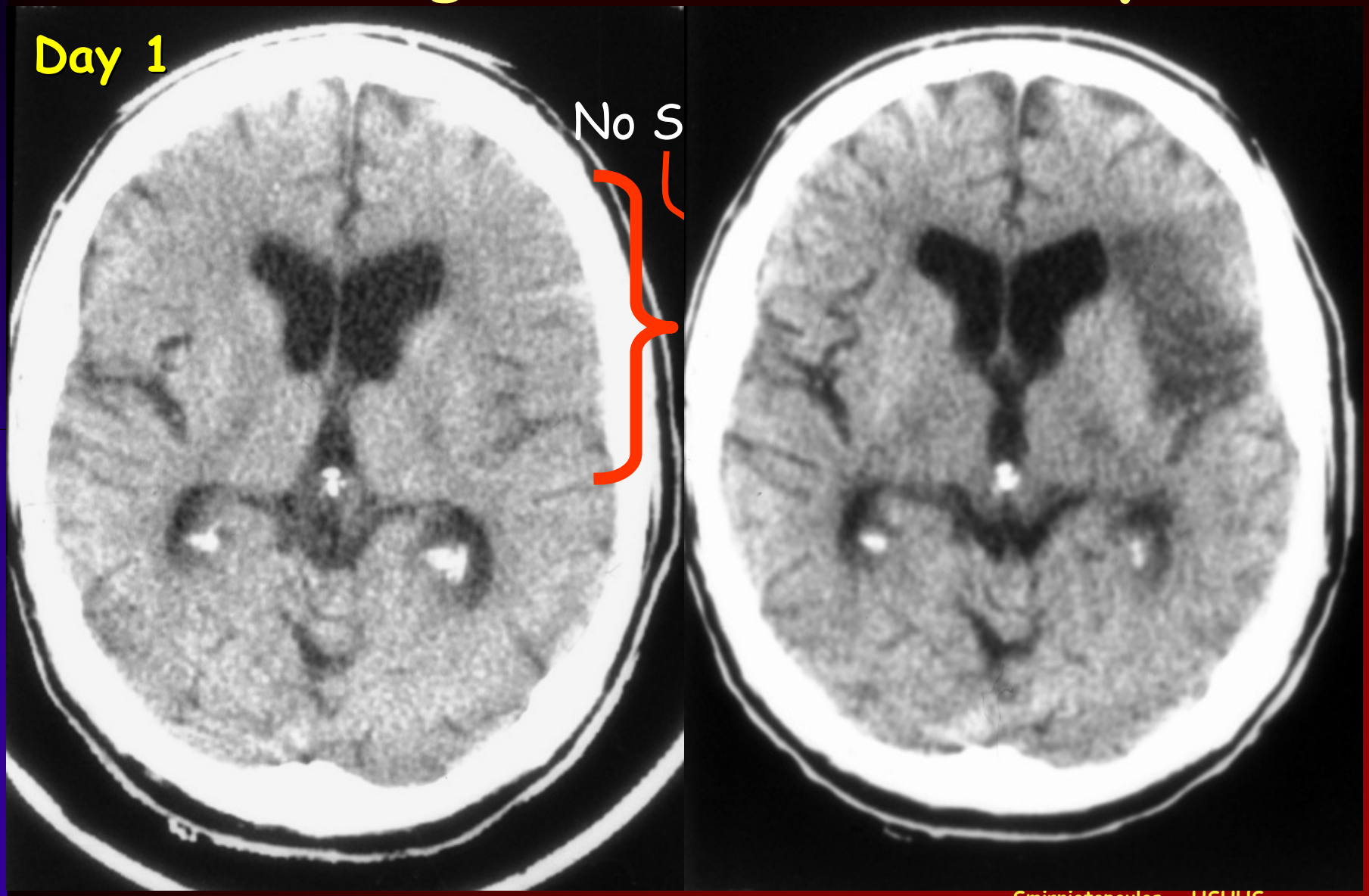

Smirniotopoulos - USUHS

Radiology - http://rad.medpix.net

Radiology - http://rad.medpix.net

Angio Lab: Major Goals

- Normal Vascular Anatomy
  - Anastomoses and Circle of Willis
  - Vascular Territory on Axial Images
- Stenosis, Occlusion, and Infarction
- Vascular Variants and Malformations
  - Fetal origin of PCA
  - AVM
  - Cavernous Angioma
  - Venous Angioma
- Aneurysm and Subarachnoid Hemorrhage
- Hypertensive Disease

Radiology - http://rad.medpix.net

ICA Lateral Angiogram

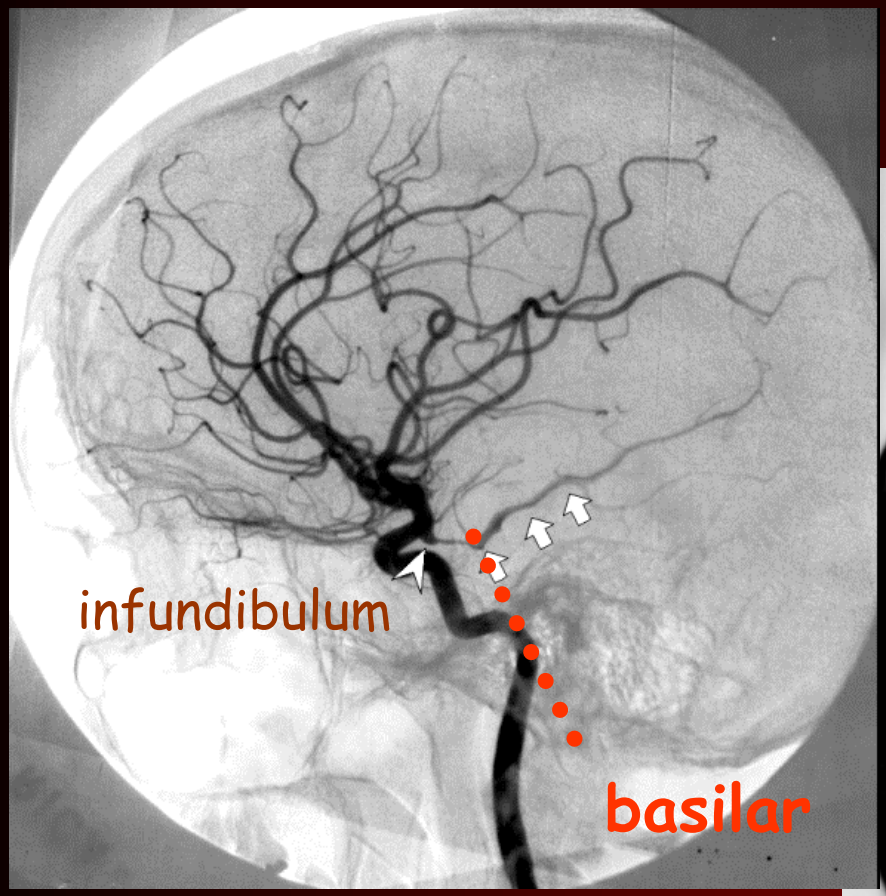

Normal PCOM and PCA

"Fetal" Origin of PCA

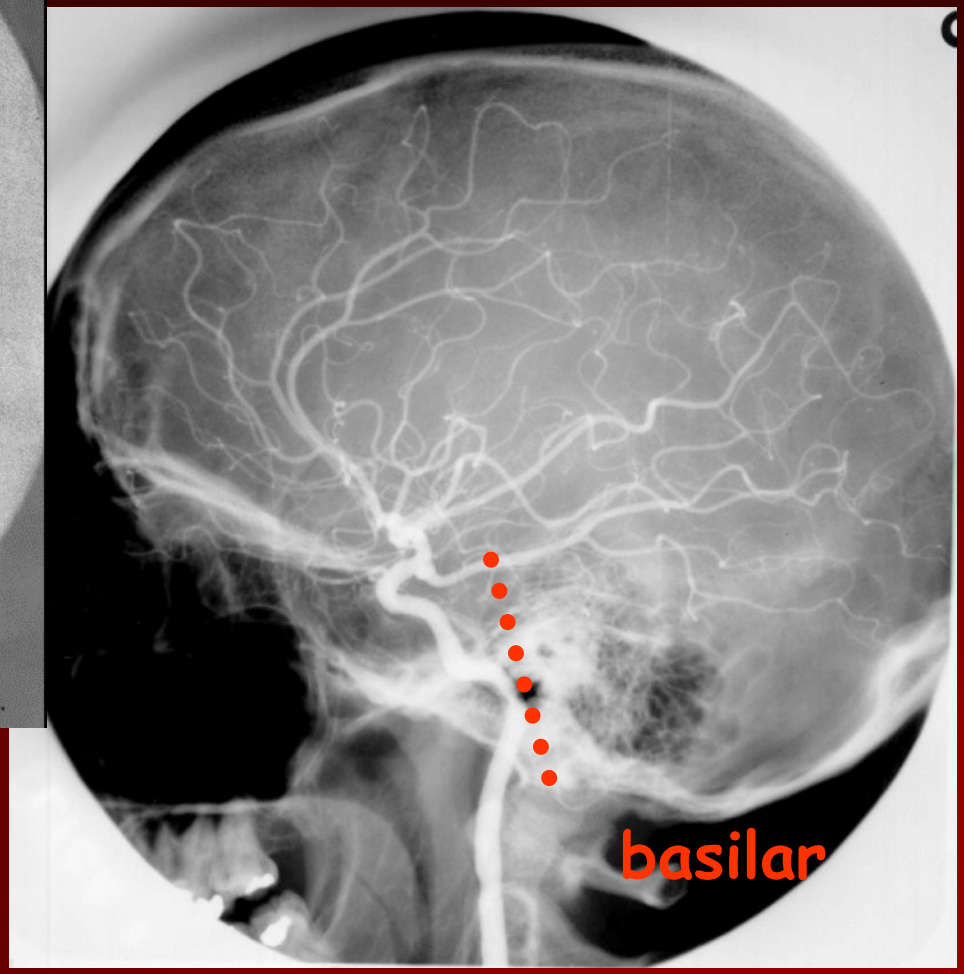

"Fetal" Origin of PCA

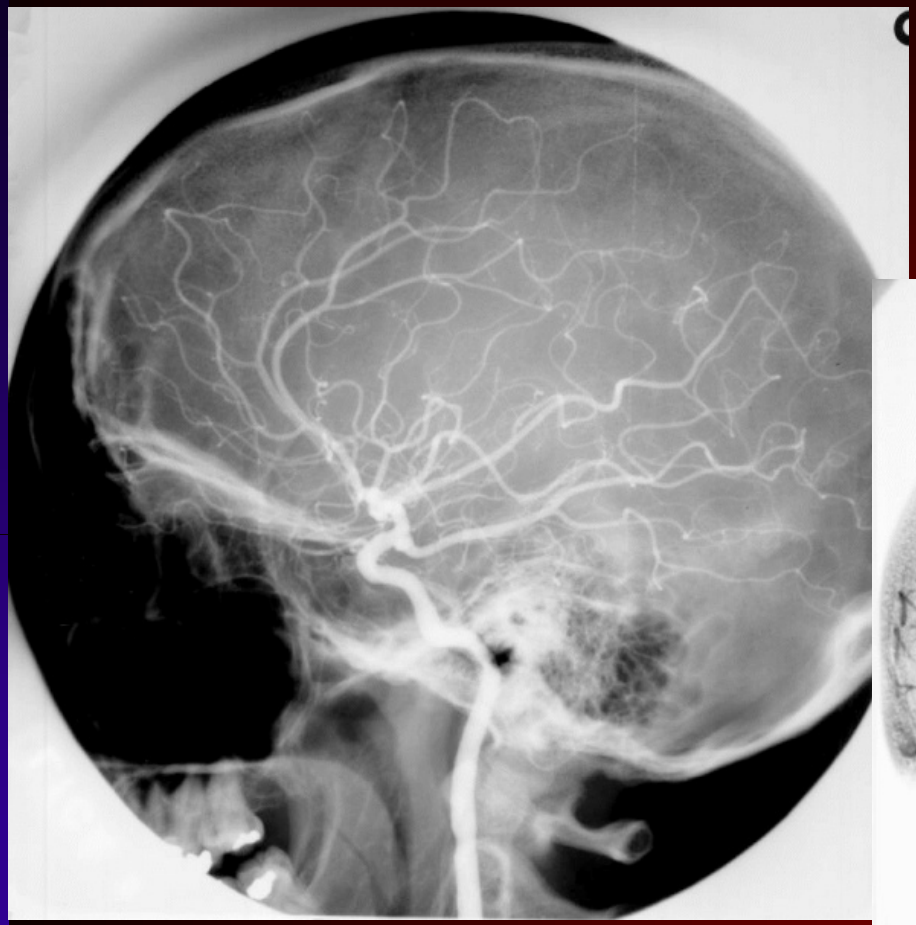

Pt 1

Pt 2

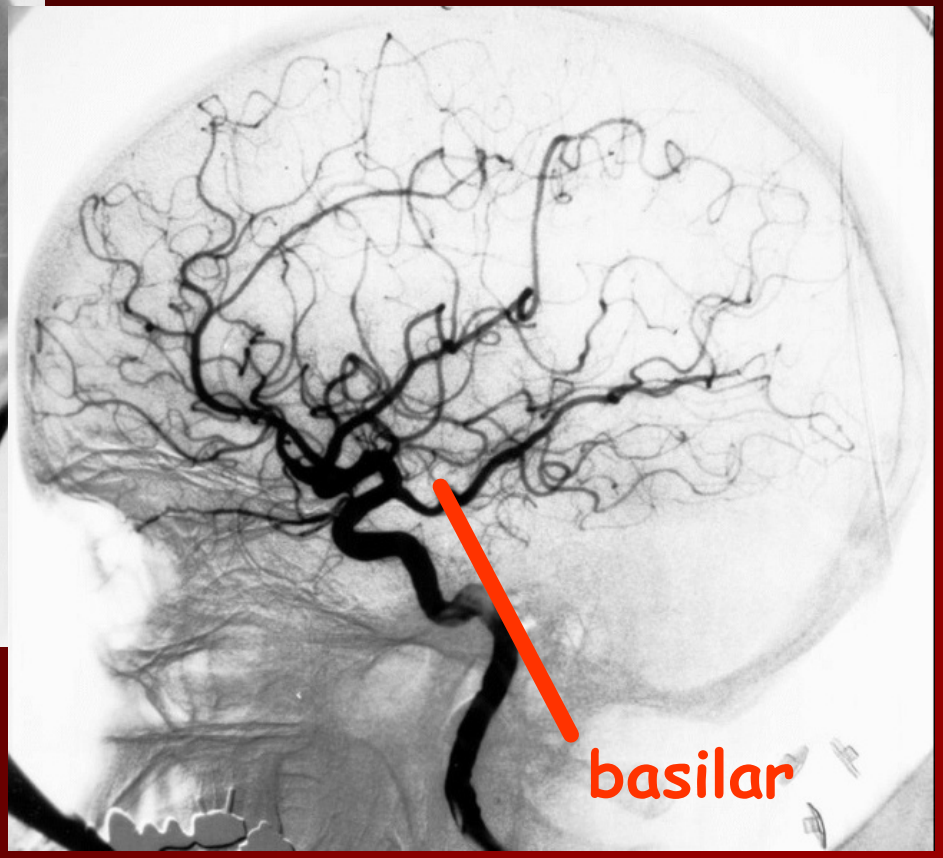

Smirniotopoulos - USUHS

Radiology - http://rad.medpix.net

Radiology - http://rad.medpix.net

Angio Lab: Major Goals

- Normal Vascular Anatomy
  - Anastomoses and Circle of Willis
  - Vascular Territory on Axial Images
- Stenosis, Occlusion, and Infarction
- Vascular Variants and Malformations
  - Fetal origin of PCA
  - AVM
  - Cavernous Angioma
  - Venous Angioma
- Aneurysm and Subarachnoid Hemorrhage
- Hypertensive Disease

Venous Angioma

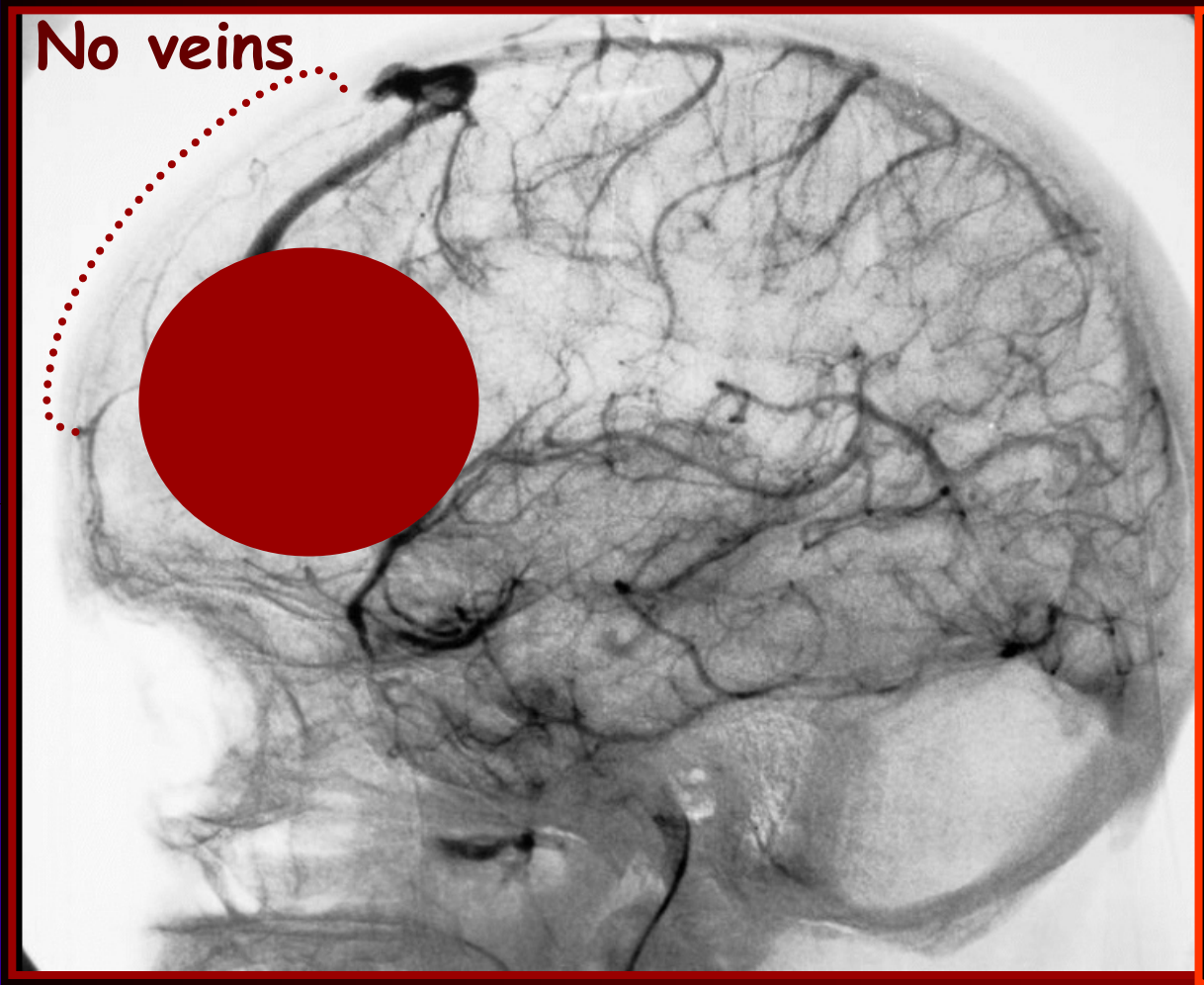

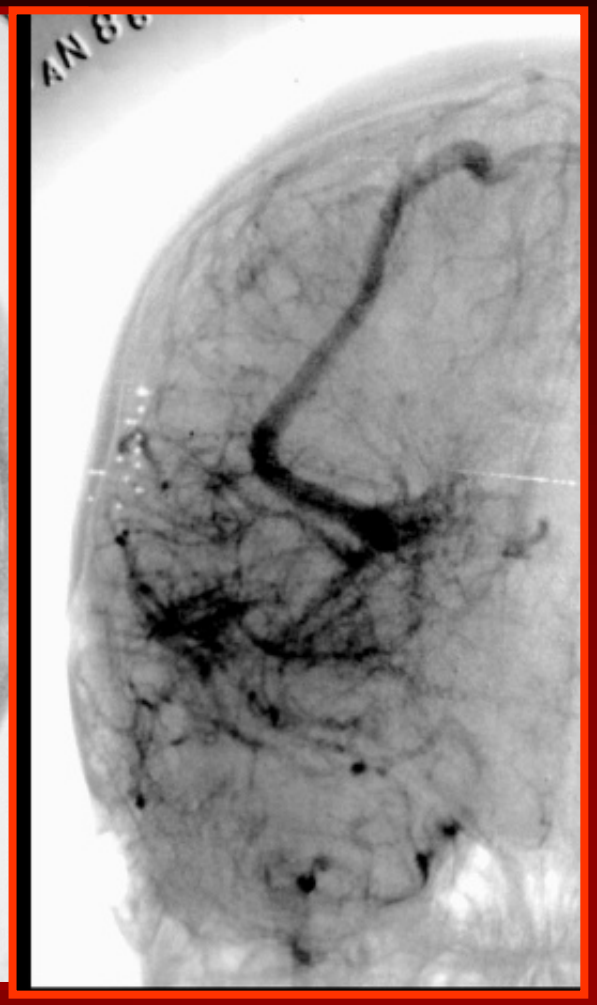

Radiology - http://rad.medpix.net

Radiology - http://rad.medpix.net

Angio Lab: Major Goals

- Normal Vascular Anatomy
  - Anastomoses and Circle of Willis
  - Vascular Territory on Axial Images
- Stenosis, Occlusion, and Infarction
- Vascular Variants and Malformations
  - Fetal origin of PCA
  - AVM
  - Cavernous Angioma
  - Venous Angioma
- Aneurysm and Subarachnoid Hemorrhage
- Hypertensive Disease

Radiology - http://rad.medpix.net

Aneurysm forms at Bifurcation

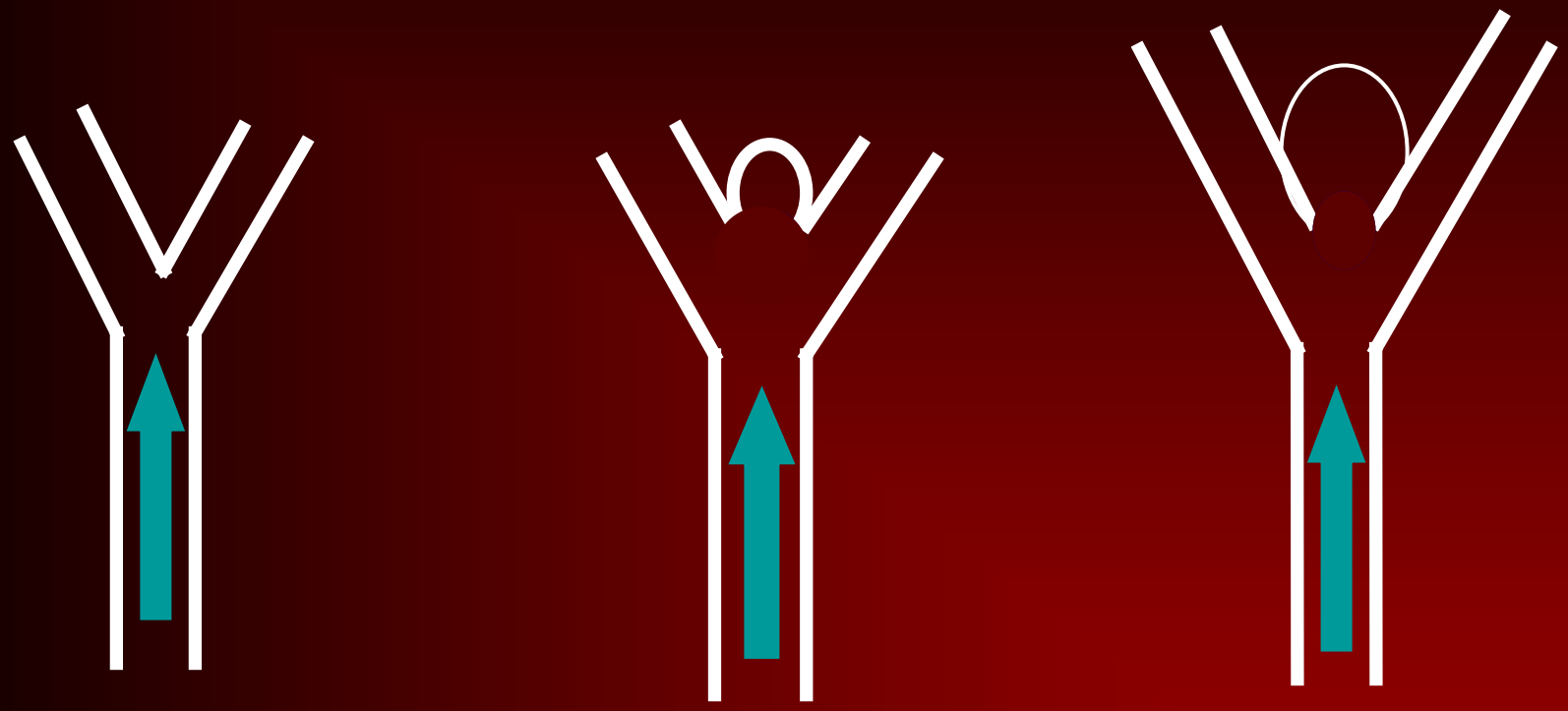

Goal!

Radiology - http://rad.medpix.net

Notice:

The bigger the aneurysm the thinner the wall

Radiology - http://rad.medpix.net

Basilar Tip Aneurysm

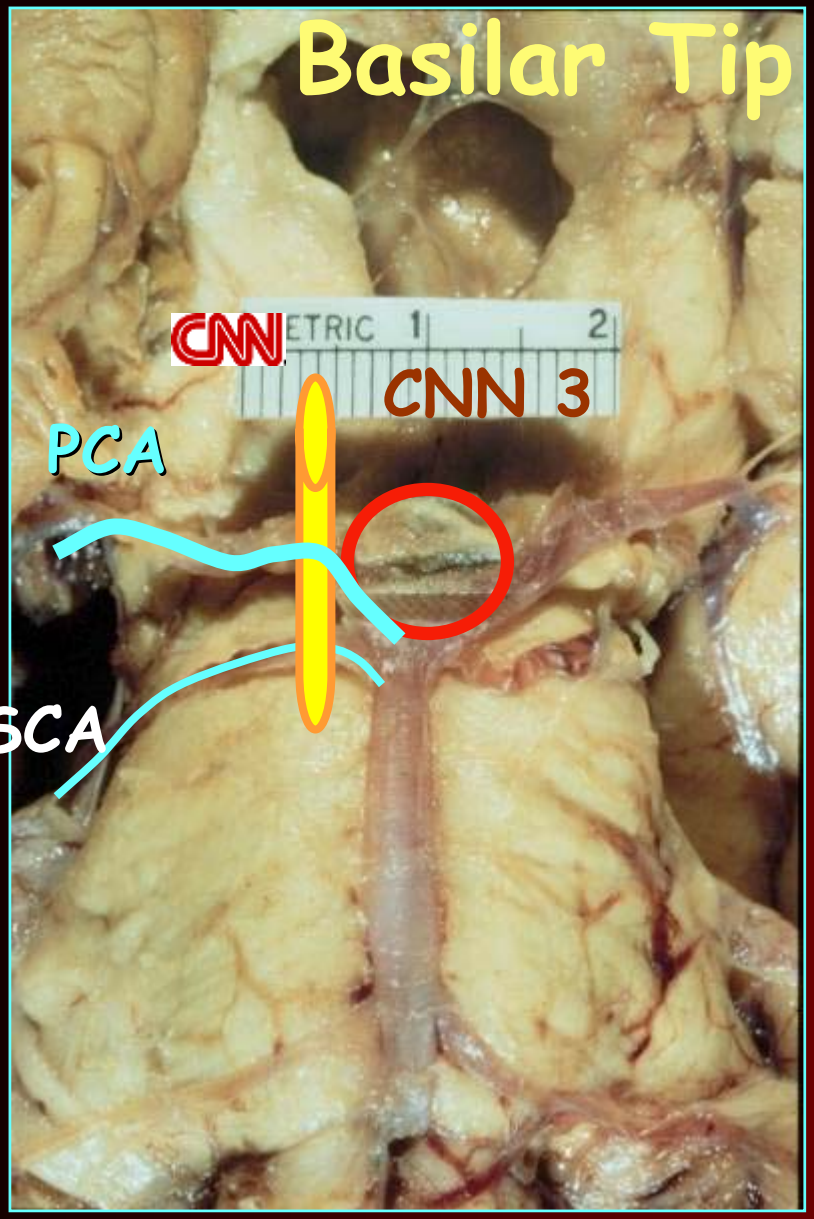



Goal!

Worst HA: Non-Contrast CT

Everyone gets a star!

Suprasellar cistern

Non-Contrast CT

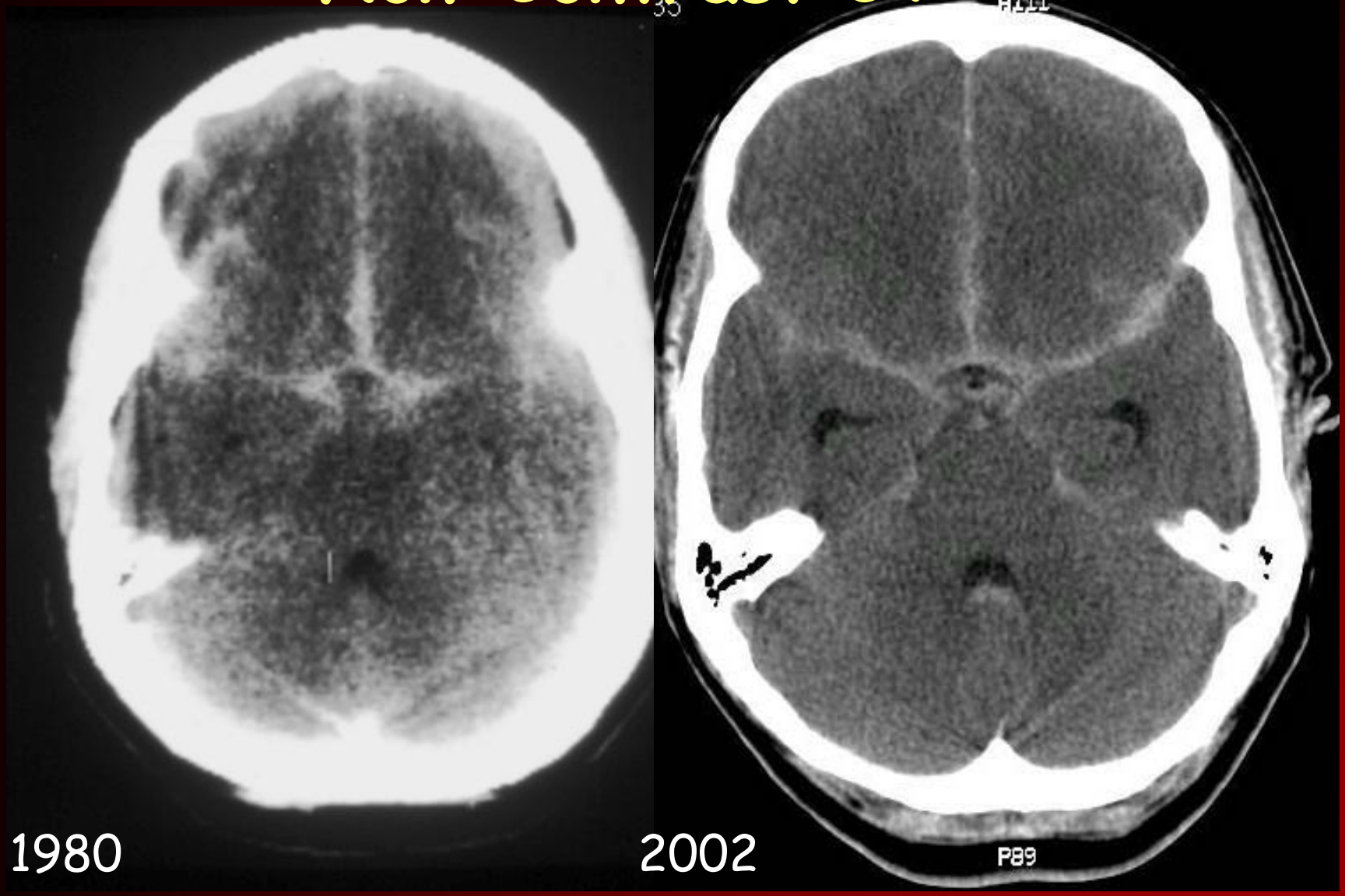

Radiology - http://rad.medpix.net

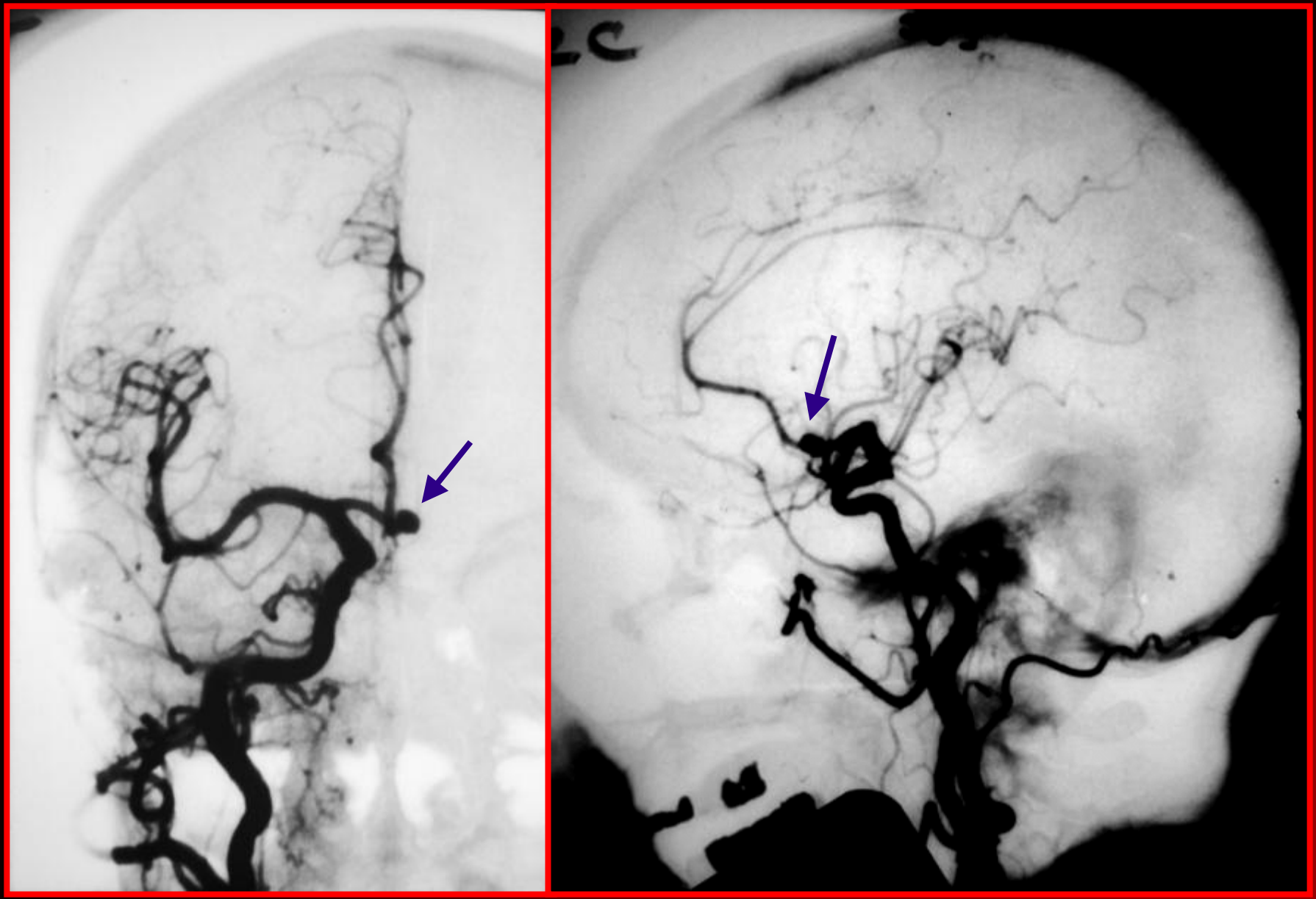

MR and CT - Carotid Aneurysm

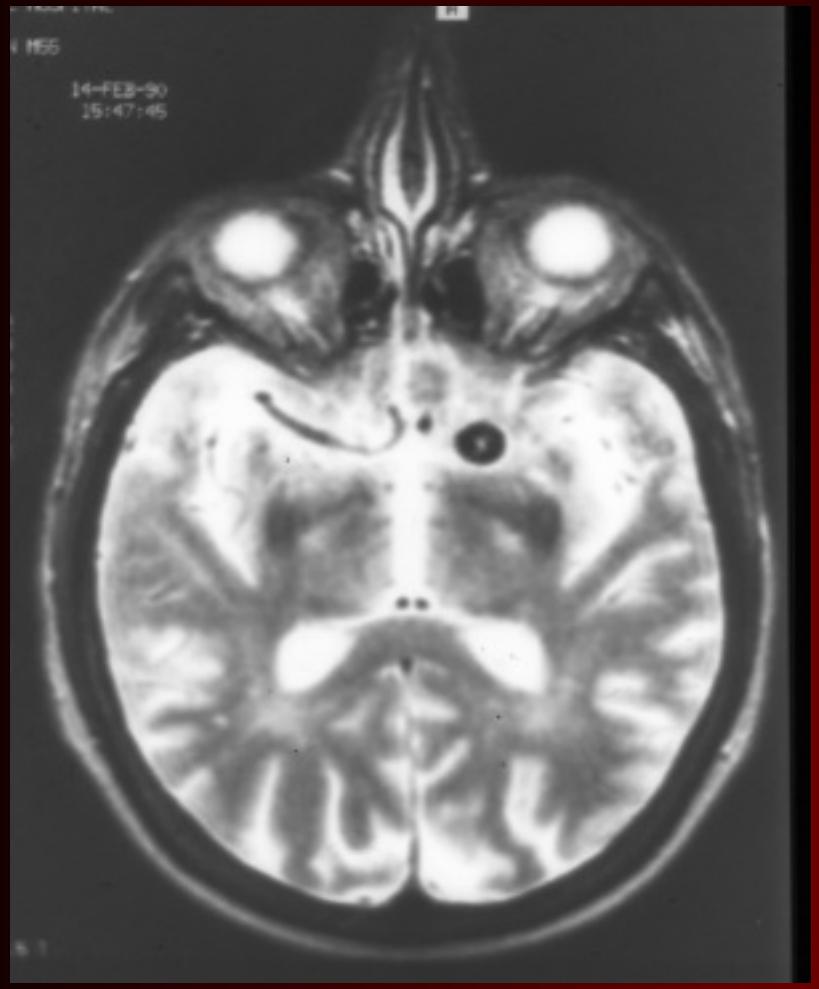

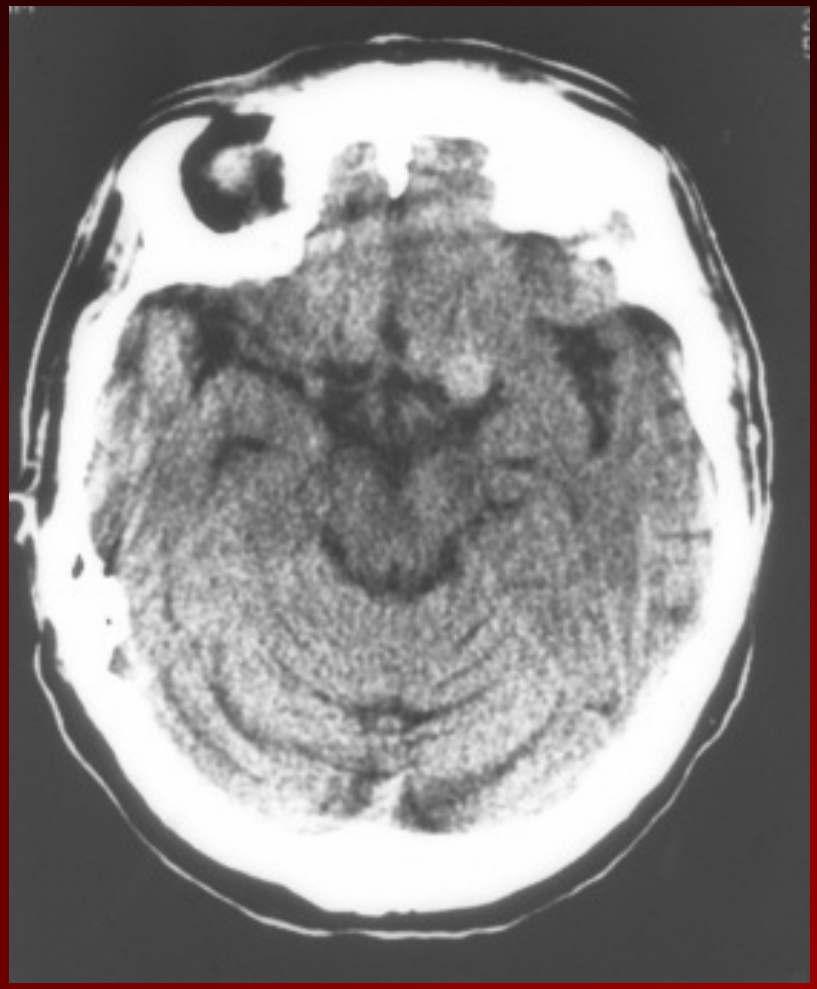

Radiology - http://rad.medpix.net

Radiology - http://rad.medpix.net

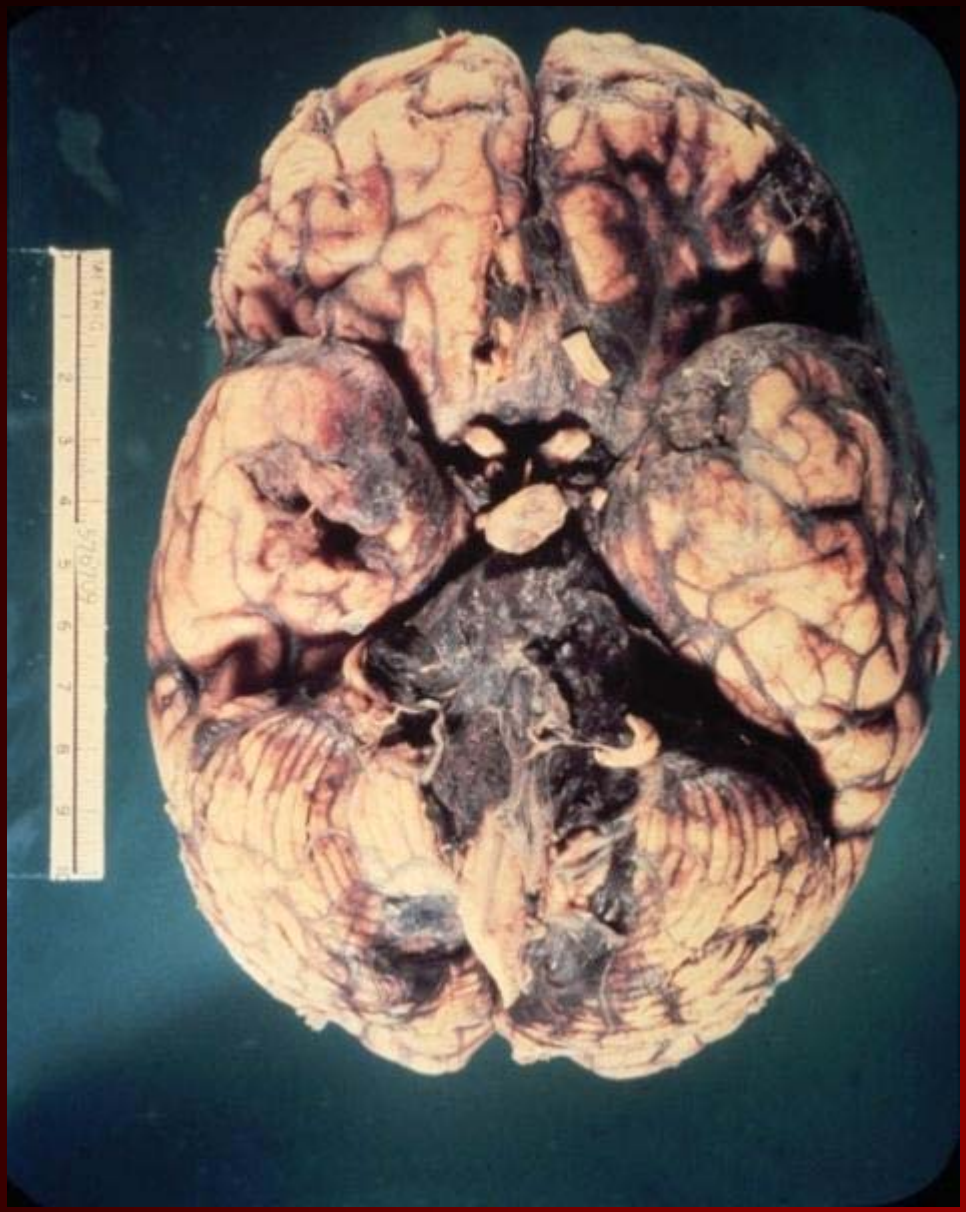

Subarachnoid Space

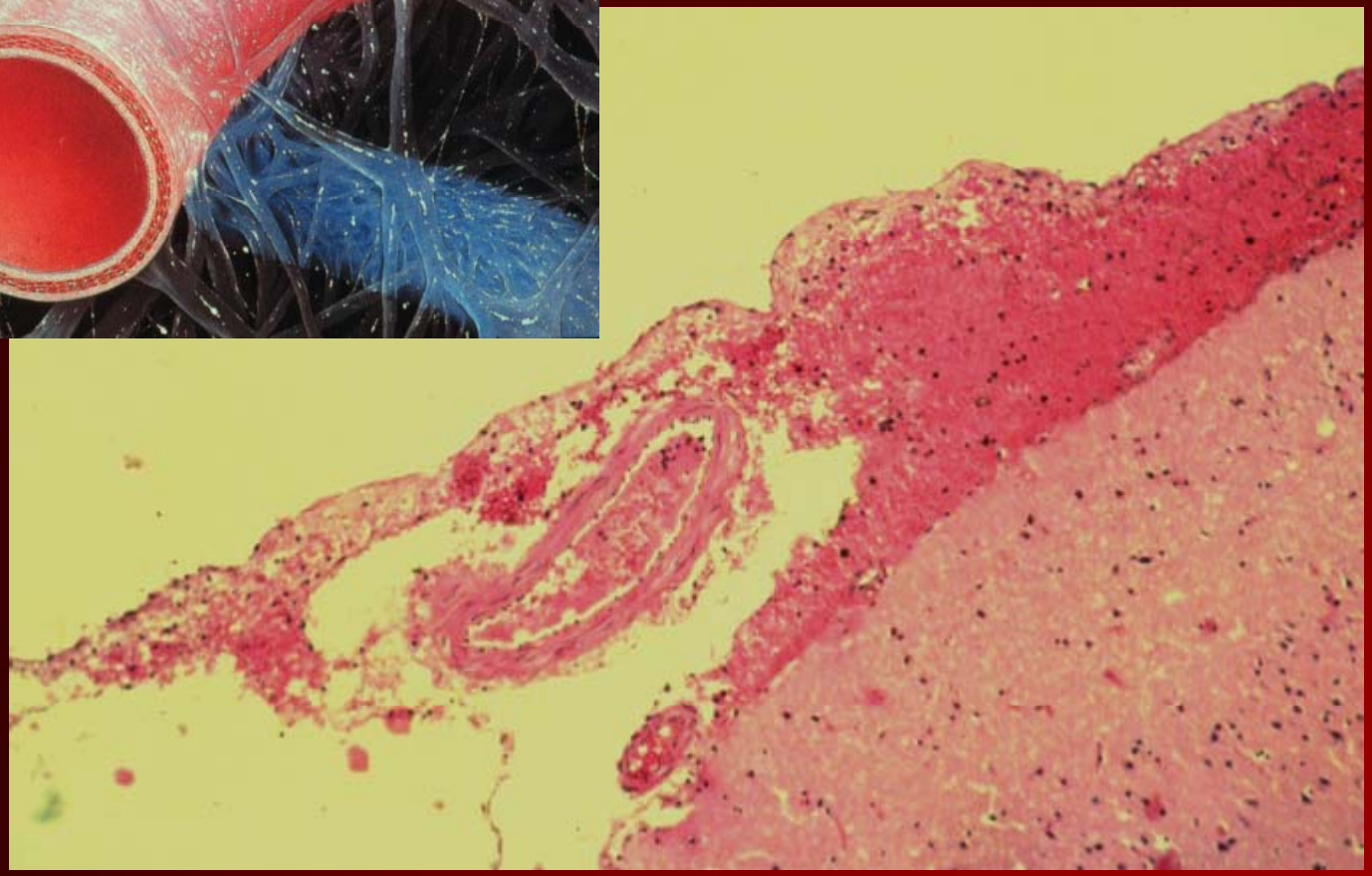

Radiology - http://rad.medpix.net

Bilateral Carotid Aneurysms

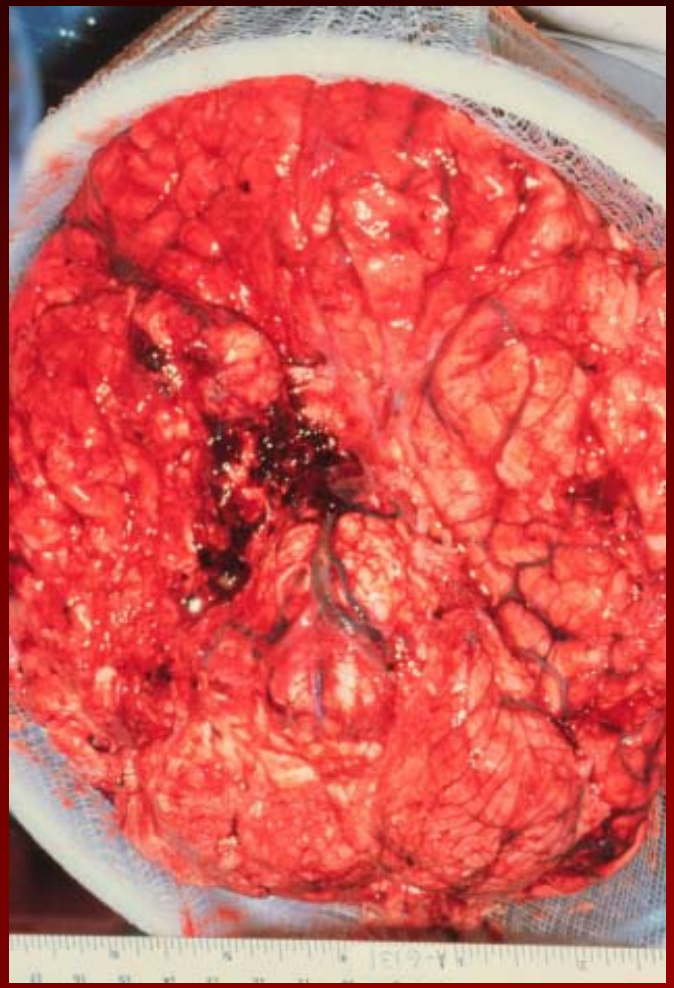

Smirniotopoulos - USUHS

Radiology - http://rad.medpix.net

Radiology - http://rad.medpix.net

Angio Lab: Major Goals

- Normal Vascular Anatomy
  - Anastomoses and Circle of Willis
  - Vascular Territory on Axial Images
- Stenosis, Occlusion, and Infarction
- Vascular Variants and Malformations
  - Fetal origin of PCA
  - AVM
  - Cavernous Angioma
  - Venous Angioma
- Aneurysm and Subarachnoid Hemorrhage
- Hypertensive Disease

Lenticulostriate Vessels

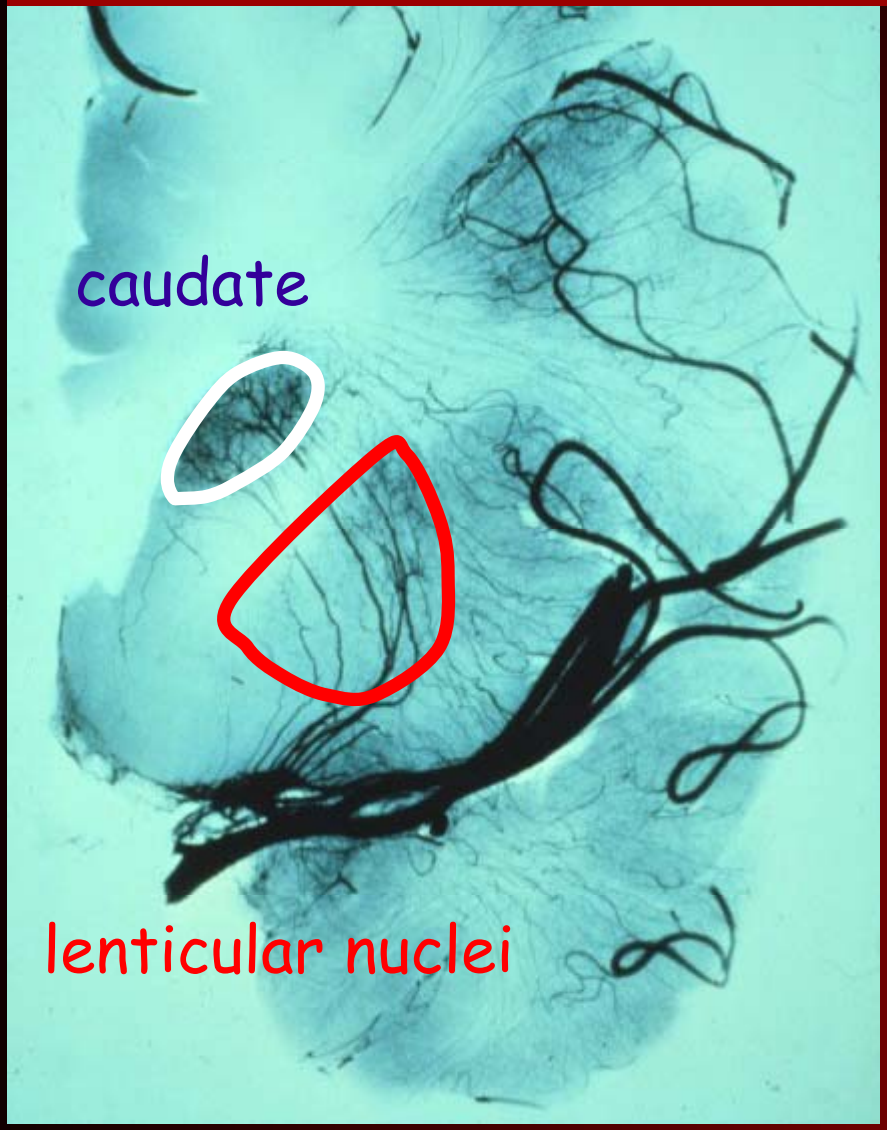

Basal Ganglia

- small caliber vessels
- non-anastomotic
- end-arteries
- arterioles

Hypertensive Disease

- hyalinized
- infarcts (lacunae)
- hemorrhage

Radiology - http://rad.medpix.net

Hypertensive Vessel Disease

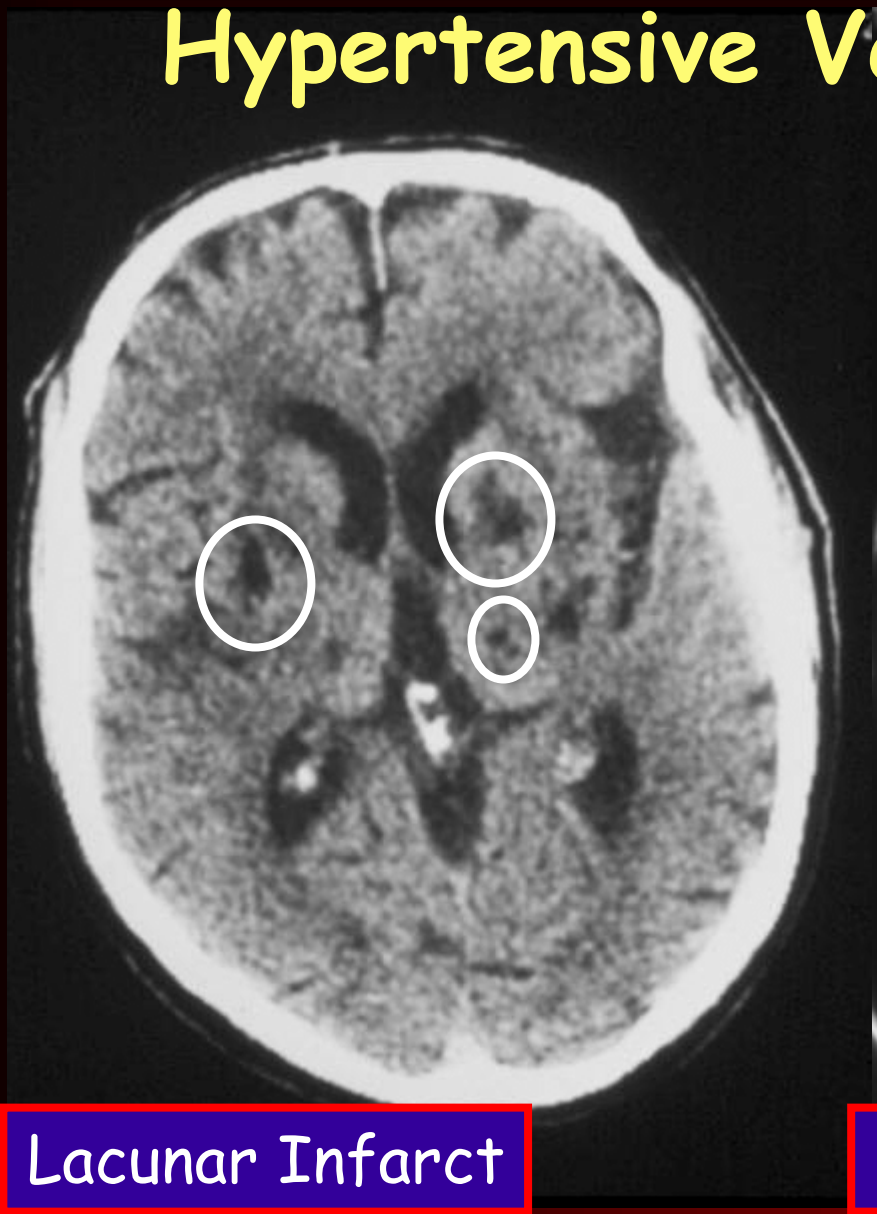

Lacunar Infarct

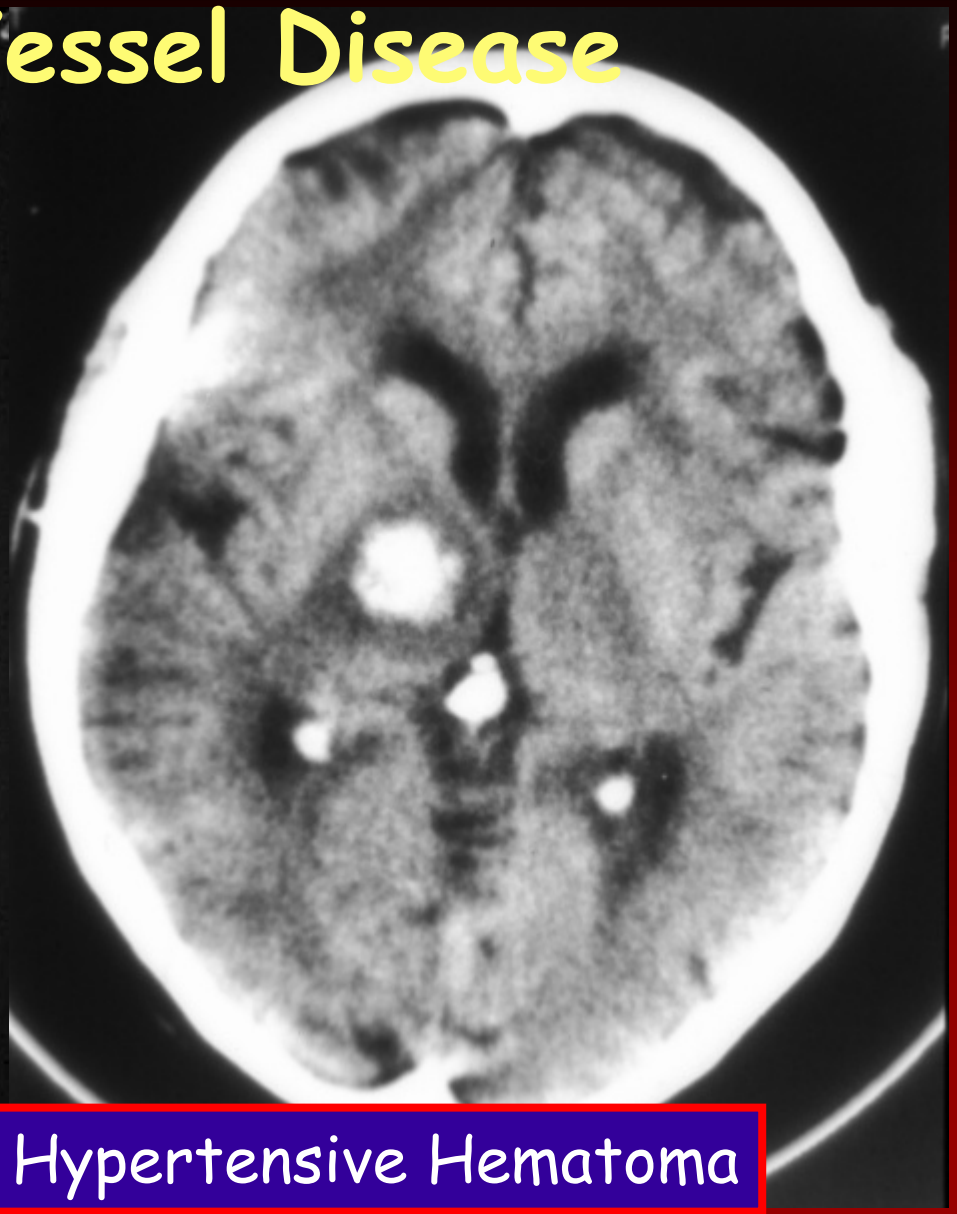

Hypertensive Hematoma

Radiology - http://rad.medpix.net

Hypertensive Hematoma in Thalamus

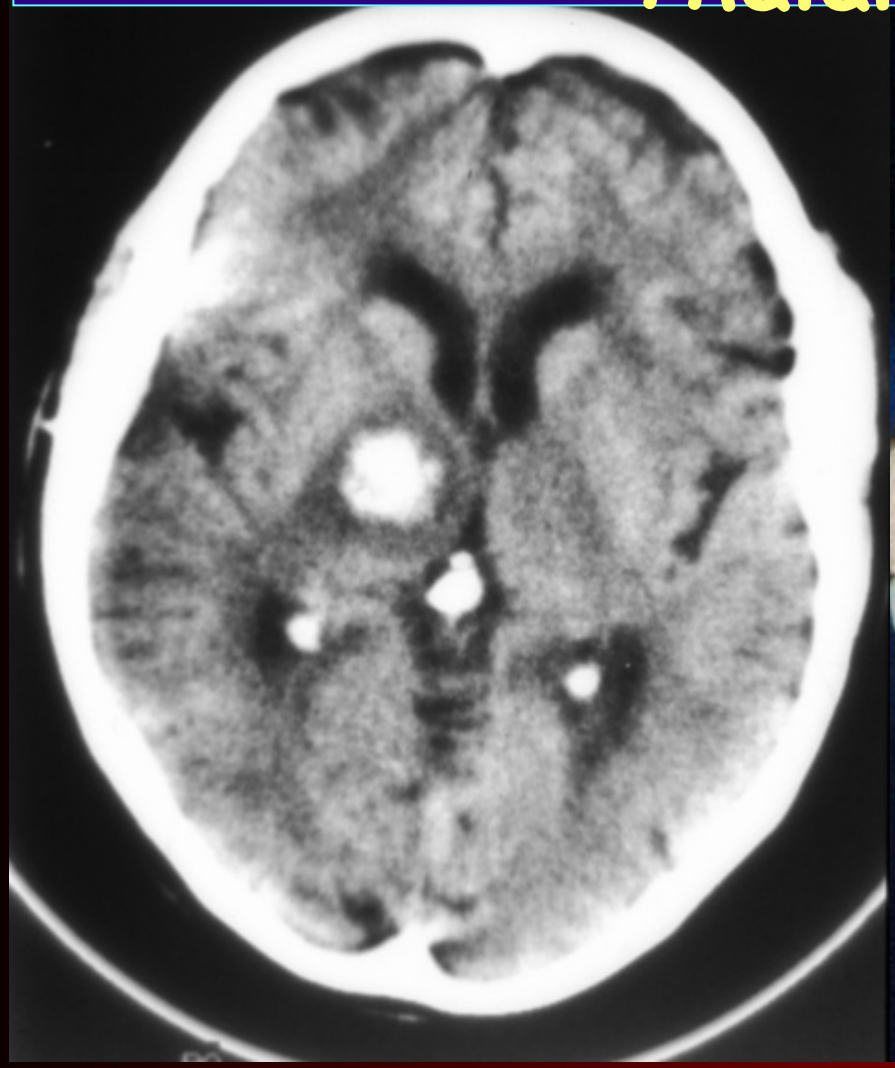

Radiology - http://rad.medpix.net

Radiology - http://rad.medpix.net

Angio Lab: Summary

- Normal Vascular Anatomy
  - Anastomoses and Circle of Willis
  - Vascular Territory on Axial Images
- Stenosis, Occlusion, and Infarction
- Vascular Variants and Malformations
  - Fetal origin of PCA
  - AVM
  - Cavernous Angioma
  - Venous Angioma
- Aneurysm and Subarachnoid Hemorrhage
- Hypertensive Disease